

SENILE PLAQUE FORMATION AND SEVERE
CARDIOVASCULAR DISEASE

CENTRE FOR NEWFOUNDLAND STUDIES

**TOTAL OF 10 PAGES ONLY
MAY BE XEROXED**

(Without Author's Permission)

CARLOS F. SONEIRA RUIZ



SENILE PLAQUE FORMATION AND
SEVERE CARDIOVASCULAR DISEASE

BY

CARLOS F. SONEIRA RUIZ

A thesis submitted to the School of Graduate
Studies in partial fulfilment of the
requirements for the degree of
Master of Science

Faculty of Medicine
Memorial University of Newfoundland

1994

St. John's
Newfoundland



National Library
of Canada

Acquisitions and
Bibliographic Services Branch

395 Wellington Street
Ottawa, Ontario
K1A 0N4

Bibliothèque nationale
du Canada

Direction des acquisitions et
des services bibliographiques

395, rue Wellington
Ottawa (Ontario)
K1A 0N4

Your file Votre référence

Our file Notre référence

The author has granted an irrevocable non-exclusive licence allowing the National Library of Canada to reproduce, loan, distribute or sell copies of his/her thesis by any means and in any form or format, making this thesis available to interested persons.

L'auteur a accordé une licence irrévocable et non exclusive permettant à la Bibliothèque nationale du Canada de reproduire, prêter, distribuer ou vendre des copies de sa thèse de quelque manière et sous quelque forme que ce soit pour mettre des exemplaires de cette thèse à la disposition des personnes intéressées.

The author retains ownership of the copyright in his/her thesis. Neither the thesis nor substantial extracts from it may be printed or otherwise reproduced without his/her permission.

L'auteur conserve la propriété du droit d'auteur qui protège sa thèse. Ni la thèse ni des extraits substantiels de celle-ci ne doivent être imprimés ou autrement reproduits sans son autorisation.

ISBN 0-612-01920-9

Canada

ABSTRACT

Senile plaques are considered by many to be the most consistent neuropathologic feature of Alzheimer's disease, but they are also present in the brains of non-demented, elderly subjects. Recent reports (Sparks et al, 1990, 1993) suggest that non-demented patients with critical coronary artery disease show a higher prevalence of senile plaques than non-demented subjects without heart disease. The present study analyzes 40 autopsy brains which were divided into three groups according to the clinico-pathological findings: an Alzheimer's disease group (n=12), a severe cardiovascular disease group (n=17) and a control group (n=11). The brain areas examined were the middle frontal gyrus, the superior and inferior watershed areas, the hippocampal formation with the transentorhinal cortex, the primary visual cortex, the head of the caudate nucleus and the anterior lobe of the cerebellum. Consecutive sections were stained with cresyl violet, the modified Bielschowsky method and immunohistochemistry for amyloid beta-protein. Senile plaques and neurofibrillary tangles were counted in three and six microscopic fields at X100 and X200 magnification, respectively, and the mean values of the counts were calculated and used for statistical analysis. Patients with severe cardiovascular disease (critical coronary artery disease and/or hypertension) showed

a higher prevalence of senile plaques than the non-demented controls. In the cardiovascular disease group senile plaque counts were significantly larger in the inferior watershed area, dentate gyrus, subiculum and transentorhinal cortex. Control and cardiovascular disease patients showed no difference regarding the prevalence and number of neurofibrillary tangles. In the sample examined, cardiovascular disease patients occupied an intermediate position in the spectrum of senile plaque formation between Alzheimer's disease and non-heart disease patients. These results suggest that there might be a cardiovascular component in the genesis of senile plaques and that study of patients with severe cardiovascular disease may help to clarify the origin and evolution of these lesions.

This thesis is dedicated to the
memory of my grandmother

ACKNOWLEDGEMENTS

It is my great pleasure to express my gratitude to my supervisor, Dr. Thomas M. Scott, for giving me the opportunity to learn in his laboratory and for making this work possible through his support, orientation and many fruitful discussions. Thanks are also due the other members of my supervisory committee, Dr. David Haegert and Dr. Alan Goodridge, for their valuable suggestions along the course of this study.

My appreciation is extended to Linda Chafe for her friendly help in many aspects of this work and to Geraldine Kufflick for her assistance in the preparation of the manuscript. I am also especially grateful to Ed Evely and to the staff of the Laboratory of Pathology of the Health Sciences Centre for their technical assistance.

I extend my sincere thanks to my co-workers in the Division of Biological Sciences of the Canadian Memorial Chiropractic College for their understanding and support during the final stages of this work.

Finally, I am especially indebted to my wife, Mariela, for giving me strength and unlimited love in spite of the circumstances that have kept us physically apart.

CONTENTS

	page
ABSTRACT	ii
AKNOWLEDGEMENTS	v
LIST OF TABLES	viii
LIST OF FIGURES	ix
LIST OF ABBREVIATIONS	xi
Chapter 1 INTRODUCTION	1
1.1) Dementia and Alzheimer's disease	1
1.2) Neuropathology of Alzheimer's disease	7
1.2.1) General features	7
1.2.2) Senile plaques	14
1.2.3) Neurofibrillary tangles	25
1.3) Neuropsychopathology of cardiovascular diseases	31
Chapter 2 MATERIALS AND METHODS	40
2.1) Description of the sample	40
2.2) Neuropathological assessment	43
2.2.1) Initial procedures	43
2.2.2) Staining methods	46
2.2.3) Quantification of SP and NFT	52
2.3) Statistical analysis	53
Chapter 3 RESULTS	55

	page
Chapter 4 DISCUSSION	89
4.1) Brain weight	89
4.2) Severe CVD and SP formation	90
4.3) Qualitative aspects and staining of SP	95
4.3.1) Primary visual cortex	99
4.3.2) Caudate nucleus	100
4.3.3) Cerebellum	103
4.4) Hippocampal formation	108
4.5) Severe CVD and SP: Pathogenetic relationship	113
4.5.1) Blood-brain barrier impairment.....	114
4.5.2) Denervating microangiopathy	119
4.5.3) Cerebral hypoperfusion	123
4.6) Summary and Conclusions	129
REFERENCES	131

LIST OF TABLES

	page
Table 2.1: Descriptive characteristics of the sample	41
Table 2.2: Description of the subgroups of CVD patients	42

LIST OF FIGURES

	page
Figure 3.1: Comparison of brain weights	56
Figure 3.2: SP in neocortical areas	58
Figure 3.3: SP in medial temporal lobe	59
Figure 3.4: NFT in medial temporal lobe	60
Figure 3.5: SP in neocortical areas (CCAD)	62
Figure 3.6: SP in medial temporal lobe (CCAD)	63
Figure 3.7: NFT in medial temporal lobe (CCAD)	64
Figure 3.8: SP in neocortical areas (HT)	65
Figure 3.9: SP in medial temporal lobe (HT)	67
Figure 3.10: NFT in medial temporal lobe (HT)	68
Figure 3.11: Diffuse plaques in the molecular layer of the subiculum of a CVD patient	70
Figure 3.12: Classic plaques in the pyramidal cell layer of the subiculum of an AD patient ...	71
Figure 3.13: Bielschowsky-stained SP in the molecular layer of the dentate gyrus of an AD patient	73
Figure 3.14: Anti-amyloid immunohistochemistry showing the same SP (as in Figure 3.13) in the molecular layer of the dentate gyrus of an AD patient	74
Figure 3.15: SP in the inferior watershed area of a CVD patient	75
Figure 3.16: SP in the molecular layer of the dentate gyrus of an AD patient	76
Figure 3.17: SP in the molecular layer of the dentate gyrus of a CVD patient	77

	page
Figure 3.18: SP in the pyramidal cell layer of the subiculum of an AD patient	78
Figure 3.19: SP in the pyramidal cell layer of the subiculum of a CVD patient	79
Figure 3.20: SP in the transentorhinal cortex of an AD patient	81
Figure 3.21: SP in the transentorhinal cortex of a CVD patient	82
Figure 3.22: SP in the primary visual cortex of an AD patient	83
Figure 3.23: SP in the head of the caudate nucleus of an AD patient	85
Figure 3.24: Diffuse plaques in the molecular layer of the cerebellar cortex of an AD patient	86
Figure 3.25: Torpedo-like swelling of the axon of a Purkinje cell in the cerebellum of an AD patient	87
Figure 3.26: Amyloid angiopathy of meningeal and parenchymal blood vessels of the cerebellum of an AD patient	88

LIST OF ABBREVIATIONS

AD: Alzheimer's disease
BBB: Blood-brain barrier
CA1: CA1 region of the hippocampus proper
CCAD: Critical coronary artery disease
CVD: Cardiovascular disease
DG: Dentate gyrus
HT: Arterial hypertension
IWA: Inferior watershed area
MFG: Middle frontal gyrus
NFT: Neurofibrillary tangles
SP: Senile plaques
Sub: Subiculum of the hippocampal formation
SWA: Superior watershed area
TEC: Transentorhinal cortex
VC: Primary visual cortex

INTRODUCTION

1.1) Dementia and Alzheimer's disease

Dementia is a clinical syndrome with many different causes. According to the American Psychiatric Association (1987), the essential feature of dementia is impairment in short- and long-term memory, associated with impairment in abstract thinking and judgement, other disturbances of higher cortical function, or personality change, in the absence of gross clouding of consciousness. The disturbance is severe enough to interfere significantly with work or usual social activities or relationships with others.

In the last decade, developments in brain imaging, precise psychological tests, immunohistological techniques, and molecular biology have greatly increased our knowledge of many aspects of the dementing syndrome, and in particular of Alzheimer's disease (AD). This explosion in investigation and knowledge has been driven not only by advancing techniques, but also by the recognition of the impact that the increasing lifespan of the population has had on social and financial structures of the economically advanced countries.

All western nations have seen great increases in both the number and the proportion of elderly individuals in their populations. As more and more people survive into old age, the

incidence of dementing illnesses, and particularly that of AD, increases, laying a greater burden on hospital services. These demographic changes and their consequences are profoundly influencing changes in the patterns of health care as well as priorities in biomedical research.

Dementia can occur at any age. It is, however, uncommon below 60 years but increases sharply in prevalence after this age. The most frequently quoted rates suggest that around 5% of the population above 65 and up to 25% of those over 80 years are demented (Tomlinson, 1992). Henderson and Kay (1984) summarized a group of important surveys on the prevalence of dementia. The actual percentage of affected people in five surveys between 1956 and 1975 was widely variable, but all revealed steep rises above 75 years and in all the surveys there was some evidence of dementia in more than 20% of people above 85 years. A more recent report (Evans et al., 1989), based on a study of noninstitutionalized individuals in East Boston, showed clinically diagnosed probable AD in 3% of subjects aged 65 to 74, 18.7% of subjects aged 75 to 84, and an astonishing 47.2% of subjects over 85 years.

In the age group over 60 years, there is a very wide variety of causes of dementia. These include cerebrovascular changes (multi-infarct dementia); central nervous system infections (tertiary neurosyphilis, tuberculous and fungal meningitis, viral encephalitis, human immunodeficiency virus-

related disorders, Creutzfeldt-Jakob disease); brain trauma (especially chronic subdural hematoma); toxic-metabolic disturbances (pernicious anemia, folic-acid deficiency, hypothyroidism); normal-pressure hydrocephalus; neurologic diseases (Huntington's chorea, multiple sclerosis, Parkinson's disease); and postanoxic or posthypoglycemic states. However, despite these many causes, the most common condition producing dementia is AD (American Psychiatric Association, 1987; Koo and Price, 1993; Tomlinson, 1992).

In an autopsy study of demented patients Tomlinson, Blessed and Roth (1970) observed that about 50% of the cases showed features of AD in a pure form. In around 15% extensive evidence of cerebral softening was the only major pathological lesion found, and in about 10% the two degenerative processes were combined. In a further 15% there were Alzheimer-like changes, with and without some cerebral softenings, but their quantitative grading was not high enough for a firm diagnosis. In about 4% other specific abnormalities such as Pick's disease or tumors were found, but no adequate morphological basis for dementia was detected in the remaining 6%.

A later study reporting on a larger group of demented patients (Jellinger, 1976) also found that dementia of Alzheimer type accounted for just over half the cases, while nearly a quarter belonged to the vascular type, and the two were combined in 13%. Cerebral tumors, Pick's disease and

other rarer conditions accounted for the remaining 12%.

These studies found that in 10 to 15% of the cases the lesions of AD and cerebral infarction occurred together to an extent that may justify the diagnosis of dementia due to mixed senile and vascular changes.

The terminology related to AD is now more or less consistent, although there are still contradictions about separating presenile from senile AD (Roth, 1985). The former is largely genetically determined and associated with severe neuropathological changes which differentiate it completely from anything seen in age-matched controls; by comparison, the latter may occur with little or no evidence of genetic determination and may present changes which are closer to those found in the normal aged brain.

Some authors prefer to use the term "Alzheimer's disease" for the presenile form that matches better the case originally described by Alois Alzheimer in 1907, while the terms "senile dementia" or "senile dementia of the Alzheimer type" have been commonly used to refer to the senile form. However, the proposed separation of AD and senile dementia has never been totally accepted, and the majority opinion now places these two disorders in one category (Tomlinson, 1992). We are going to accept this general criterion, and the term "Alzheimer's disease" will be used throughout this work to refer to both the presenile and senile forms.

Clinically, AD is characterized by an insidious onset and a progressive and deteriorating course. In the early stages, memory impairment may be the only apparent cognitive deficit. There may also be subtle personality changes, such as apathy, lack of spontaneity, and quiet withdrawal from social interactions. People usually remain neat and well-groomed, and, aside from an occasional irritable outburst, are cooperative and behave in a socially appropriate way. Disturbance of speech functions can be also an early symptom (e.g., anomia, echolalia, difficulty in comprehending written or oral speech). If the patient has insight into the deterioration, he may become depressed, and depression occurs in about 25% of the patients. With progression of the disease, various cognitive disturbances become quite apparent, and behavior and personality are more obviously affected. By the late stage, the person may be completely mute and inattentive. At this point the patient is totally incapable of caring for himself and many are partly or completely incontinent. In many, but not all patients, there is extreme wasting. Terminal bronchopneumonia is the commonest postmortem finding to which death is immediately attributable (American Psychiatric Association, 1987; Katzman, 1989; Tomlinson, 1992).

Women are affected more often than men, the proportion being about 2:1 (Aronson et al., 1990; Rocca, Amaducci and Schoenberg, 1986; Tomlinson, 1992). The duration of the

illness is variable, but it is considered to be 5 years on average. Occasional cases survive only a few months, but survival as long as 21 years has been recorded. It has been observed that progression of the disease in presenile-onset cases is faster than in senile-onset cases (Seltzer and Sherwing, 1983).

A field that has attracted increasing interest is that of potential risk factors for AD. So far, the most convincing association with AD, beyond increasing age, is the presence of a family history of dementia (Henderson, 1990; Mohs et al., 1987). A recent study (Mendez et al., 1992) showed similar results, the AD patients had more first-degree demented relatives than the non-AD dementia group or the normal elderly cases, but surprisingly, in the group of AD patients with a family history of dementia the disease started at a later age than in those without an affected relative, a finding that contradicts the more traditional view which considers family history of dementia more closely related to early-onset AD than to late-onset AD (Breitner et al., 1988).

Two other factors seem to be also associated with increased risk for AD: head trauma and Down's syndrome (Horvath et al., 1989), although the validity of the former has been questioned by some studies (Aronson et al., 1990; Mendez et al., 1992). The presence of Alzheimer-type histological lesions in all Down's syndrome patients who die

over the age of 30 years (Malamud, 1972; Wisniewski, Wisniewski and Wen, 1985) has suggested that the pathological process in Down's syndrome from early middle life is similar to that occurring in AD several decades later. This probable link has given additional support to the genetic hypotheses of AD and has become stronger after discovering that the gene coding for the precursor molecule of beta-amyloid protein is located on chromosome 21 (Goldgaber et al., 1987).

At the same time, studies with monozygotic twins have shown that concordance for AD is less than 60%, indicating that other factors, probably enviromental (e.g., toxic, infectious), play an important role in the pathogenesis of the disease (Horvath et al., 1989; Katzman, 1984, 1989).

1.2) Neuropathology of Alzheimer's disease

1.2.1) General features

Grossly, the brain of patients with AD is usually strikingly atrophic, particularly in presenile cases, averaging about 1000 g. This results in an abnormally large subarachnoid space, with pools of cerebro-spinal fluid separating the arachnoid from the retracted cortex, and enlargement of the ventricles. The cortical atrophy is usually

symmetrical and although to some degree generalized, tends to affect particularly the frontal and temporal lobes (American Academy of Neurology, 1980; Tomlinson, 1992). Some studies, however, have shown posterior parietal atrophy to be most marked (Brun and Englund, 1981; de la Monte, 1989), a result that correlates with in vivo reports of reduced metabolic activity and blood flow in the temporoparietal region of AD patients (Burns et al., 1989; Eberling et al., 1992; Friedland et al., 1987; Jobst et al., 1992; Prohovnik et al., 1988). The degree of shrinkage, in general, is far from constant and may occasionally be absent, particularly in old age, even though widespread histological evidence of AD is found (Tomlinson, 1992).

According to Corsellis (1976), the average reduction in volume of the cerebral hemispheres in elderly women with AD is about 18%. Hubbard and Anderson (1981) observed that in older AD patients (more than 80 years) cerebral atrophy was less marked and largely affected the temporal lobes by comparison with the younger group in which the gyral atrophy was more diffuse and significantly greater.

A more recent and very detailed work (de la Monte, 1989) showed reduction in cross-sectional area (7% to 19%) at five different levels of the brains of AD patients. The loss of cerebral cortex ranged from 13% to 24% and that of white matter from 3% to 19%. Ventricular enlargement, greatest in

the occipital slices, was present in all the Alzheimer cases. The author concluded that in AD the cerebral hemispheres undergo a degree of collapse or contraction along with the progressive atrophy, this observation being supported by the fact that the relative dilatation of the ventricular system was considerably less than would be expected on the basis of tissue loss.

There is still some doubt about whether the cortical atrophy in AD involves narrowing of the cortical ribbon, or shortening of cortical length or a combination of both. Many older textbooks stressed the marked narrowing of the cortical ribbon as an important factor leading to cortical atrophy, but Tomlinson (1992) mentioned that his personal observations have never confirmed that this is obvious, except in the medial temporal cortex. Furthermore, two quantitative studies (Duyckaerts et al., 1985; Najlerahim and Bowen, 1988) have concluded that reduction in cortical length is a major factor in cortical atrophy.

Microscopically, AD is characterized by the presence of numerous senile plaques (SP) and neurons containing neurofibrillary tangles (NFT) throughout most areas of the cortex and in many subcortical nuclei. In the hippocampus, numerous pyramidal cells are affected by granulovacuolar degeneration, and many Hirano bodies are present. Loss of neurons, particularly large neurons, is severe in some parts

of the cortex and hippocampus and in some deep nuclei, especially the basal nucleus of Meynert and the locus coeruleus. Deposition of amyloid within the wall of blood vessels (congoophilic or amyloid angiopathy) is seen in the majority of cases of AD. A degree of leuko-araiosis is also frequently present (American Academy of Neurology, 1980; Horvath et al., 1989; Katzman, 1989; Koo and Price, 1993; Tomlinson, 1992).

In order to make clearer the general picture of the histological changes that characterize AD, the particular pathological alterations will be described briefly in this section. A more detailed description of SP and NFT follows this section.

- Senile plaques:

Senile plaque is the term most frequently used to name the lesions originally described by Bloq and Marinesco in 1892. They are spherical areas of altered neuropil of up to 200 micrometers in diameter that typically consist of a central core of extracellular amyloid-like material surrounded by swollen nerve processes (dystrophic neurites). "Reactive cells" (astrocytes, macrophages or microglial cells) are always included in the plaque area in variable numbers. SP are difficult to see in sections stained with hematoxylin and eosin or cresyl violet, but easily demonstrated with silver techniques (Bielschowsky, Bodian, von Braunmuhl), Congo red,

thioflavin S or immunohistochemistry for amyloid beta-protein (American Academy of Neurology, 1980; Koo and Price, 1993; Tomlinson, 1992).

- Neurofibrillary tangles:

These lesions were described for the first time by Alzheimer in 1907. In light microscopic preparations the tangle appears as a thickening and tortuosity of fibrils within the neuronal cytoplasm. As with SP, these lesions are not easy to see in sections stained with hematoxylin and eosin or cresyl violet. They are most readily seen in large neurons using silver techniques, thioflavin S or antibodies raised against different components of paired helical filaments (American Academy of Neurology, 1980; Koo and Price, 1993; Tomlinson, 1992).

- Granulovacuolar degeneration:

This change, originally described by Simchowicz in 1911, is largely confined to the pyramidal cells of the hippocampus and consists of one or more vacuoles, 3 to 5 micrometers in diameter, in the cytoplasm of these neurons. Each vacuole contains a single, central granule that measures 1 to 2 micrometers. Clusters of vacuoles may cause the neuron to bulge and displace the nucleus to an eccentric location. The change is easily seen with hematoxylin and eosin and in many silver impregnations when the granule is intensely stained (American Academy of Neurology, 1980; Tomlinson, 1992).

According to Tomlinson and Kitchener (1972), granulovacuolar degeneration is rarely found before the age of 65, but after that it occurs increasingly often in non-demented patients, and by the ninth decade it can be identified in 3 out of 4 cases, although no more than 9% of the cells of the Sommer's sector are affected. This contrasted markedly with the series of demented patients in which over 20% of cells in the Sommer's sector were commonly involved. The fact that some antibodies that react with NFT also immunostained the granules (Dickson et al., 1987) has suggested that granulovacuolar degeneration possibly represents autophagy of proteins of cytoskeletal origin or phosphorylated epitopes of such proteins, and therefore has some relationship with other manifestations of abnormal cytoskeletal proteins which occur in older individuals, AD and other neurodegenerative disorders of later life.

- Hirano bodies:

Hirano bodies can readily be identified in hematoxylin and eosin stained sections. They were first identified by Hirano and co-workers in 1966 and tend to be brightly eosinophilic bodies, ovoid in shape, and 10 to 30 micrometers in length by 8 micrometers across. They occur in intellectually normal old people and in AD patients, and although there is a considerable overlap between them, the latter group is significantly more involved. Hirano bodies are

most often found among and usually adjacent to the hippocampal pyramidal cells. Ultrastructurally, they consist of parallel filaments (60 to 100 nm in length) which alternate with longer sheet-like material. Their location in relation to neurons is debatable, but with electron microscopy they often seem to indent, rather than to occupy the perikaryon (Tomlinson, 1992). The size of the filaments in Hirano bodies and their positive immunoreactions to actin and actin-associated proteins (Galloway, Pery and Gambetti, 1987) suggests that they result from an abnormal configuration of microfilaments.

- Leuko-araiosis:

Leuko-araiosis is the term applied to rarefaction of the white matter, largely periventricular in distribution and well seen on computerized tomography. It has been described in both demented and non-demented patients. Brun and Englund (1986) identified the lesion in 60% of cases of AD in a postmortem study, and a similar figure (55%) was reported by Aharon-Peretz, Cummings and Hill (1988) in a computerized tomography study. Microscopically, the lesion is characterized by partial loss of myelin, axons and oligodendroglia cells but with only slight astrocytic gliosis and macrophage infiltration (Tomlinson, 1992).

1.2.2) Senile plaques

The most striking feature of the cerebral cortex in AD is the presence of SP which may occur in vast numbers. The presence of numerous neocortical SP, alone, is considered by many authors to be enough to make the pathological diagnosis of AD, and well recognized histological criteria are based on quantitative or semiquantitative assessment of plaque density and its correlation with the age of the patient (Kachaturian, 1985; Mirra, Hart and Terry, 1993). Others suggest that the diagnosis can be made only when numerous SP and NFT are present in the neocortex (Tomlinson, 1982); however, Terry and co-workers (1987) found that 30% of cases above 74 years had no tangles in the neocortex, and considered that patients with and without tangles were not different on clinical or neurochemical grounds.

Several varieties of plaques have been described depending on the predominance of one or the other of their constituting elements. The features of the so called "classic" plaque have already been described. "Primitive" plaques consist of a small number of distended neurites with either no central amyloid fibrils or only a small number. The third type, the "burnt out" plaque, consists of a dense focus of amyloid-like material with very few or no detectable abnormal neurites at its periphery (Probst et al., 1987; Terry and

Wisniewski, 1970). Electron microscopy has identified some of the swollen neurites as axonal terminals, but according to recent immunocytochemical observations, many abnormal dendrites also seem to terminate in SP (Tomlinson, 1992).

Another form of amyloid deposition also occurs in normal individuals and in patients with AD. These lesions have received different names (diffuse plaques, preamyloid deposits, senile plaque-like structures, very primitive plaques) and can be demonstrated using the modified Bielschowski stain, the periodic acid-methenamine silver stain, or by immunostaining with antibodies raised against beta-amyloid protein (the main component of amyloid fibrils of SP and congophilic angiopathy). They are seen as ill-defined and more or less circular areas of fine fibrillary, amorphous or granular material with no swollen neurites and occasional morphologically normal neurons (Probst et al., 1987; Yamaguchi et al., 1988a, 1988b). Probst et al. (1987) also reported the presence of a central cell (probably microglial) in 15 diffuse plaques reconstructed by means of serial sections and suggested that this cell is an essential component of this type of plaque and might have a role in its pathogenesis.

Diffuse plaques, which are believed to represent a precursor to SP, occur in the cerebral cortex in great number in AD, but they can also be found in regions where classic plaques are few, such as the brain stem, basal ganglia and

cerebellum (Cole et al., 1993; Joachim, Morris and Selkoe, 1989; Mann et al., 1990; Suenaga et al., 1990; Yamazaki et al., 1992).

Electron microscopy has failed to demonstrate that this diffusely staining material consists of recognizable amyloid filaments. Joachim, Morris and Selkoe (1989) did not find any ultrastructural abnormality that could be correlated with the modified Bielschowsky stained and beta-amyloid protein reactive lesions observed on light microscopy. A more recent study of cerebellar diffuse plaques (Yamazaki et al., 1992) showed that although immunoelectron microscopy demonstrated many immunoreactive substances in the plaques, routine electron microscopy showed only very small amounts of amyloid fibrils in a few diffuse plaques.

SP may be found in an increasing proportion of people from middle age onwards, particularly in the anteromedial part of the temporal lobe including the amygdaloid nucleus. Tomlinson, Blessed and Roth (1968) and Mann, Tucker and Yates (1987) identified SP in 50% of individuals in their 60s and in 82% of individuals in their 70s. Using anti-beta-amyloid antiserum in sections of the frontal lobe, Ogomori et al. (1989) found no plaques in individuals under 50 years of age, but 40% of those in their 60s, 44% of those in their 70s, and 78% of those in their 80s showed SP. These lower figures could be attributable to using only sections of the frontal lobe,

because the first appearance of SP in many cases occurs in isolated areas of the brain, especially in the temporal lobe. More recently, Arriagada, Marzloff and Hyman (1992) studied the brains of 25 non-demented individuals (48 to 103 years, mean age 71.8 years) and found SP in 11 of them, but the degree of SP pathology did not correlate with age.

It is important to mention that plaque counts equal to those found in AD can occur in intellectually well preserved old people. Katzman et al. (1988) studied the brains of 137 previous residents of a nursing facility (108 demented, 29 non-demented) and found that one-third of the non-demented subjects (mean age 86.7 years) had pathological features of mild AD. These subjects showed plaque counts that were 80% of those of demented patients with AD. A higher figure was reported by Crystal et al. (1988). They found plaque counts greater than 30 SP/mm² in the frontal cortex of 6 out of 9 non-demented subjects (two-thirds), although their sample was smaller than that of Katzman et al.

In a study of 20 French centenarians (15 non-demented and 5 demented) beta-amyloid deposits were found in the parahippocampal and superior temporal gyri of all the cases, whatever the clinical state, and the density of the lesions was not correlated with the severity of the mental deterioration (Delaere et al., 1993). Another recent paper (Giannakopoulos et al., 1993) reported on a series of 31

elderly patients (7 with AD and 24 with no or very mild cognitive impairment) aged from 96 to 102 years. They studied the hippocampus, entorhinal cortex, superior frontal and inferior temporal gyri, and observed that the densities of SP were comparable in both groups (demented and non-demented), with no direct correlation between the number of SP and the clinical manifestation of AD.

In advanced cases of AD, no area of the cerebral cortex may be totally spared, although the concentrations of plaques in the medial temporal cortex and the amygdaloid complex often appear to be greater than elsewhere, and the primary motor and somatic sensory cortical areas are scarcely affected. SP are also found within the majority of subcortical gray structures, particularly in the walls of the third ventricle, the mamillary bodies and the tegmentum of the midbrain (Arnold et al., 1991; Esiri, Pearson and Powell, 1986; Pearson et al., 1985; Tomlinson, 1982, 1992). Diffuse plaques or preamyloid deposits are more widely distributed than classic plaques throughout the brain. They can be found in the cortex, neostriatum, globus pallidus, thalamic nuclei, brain stem, cerebellar cortex, and upper spinal cord (Bugiani et al., 1989).

Plaques can occur in all layers of the cerebral cortex, but with conventional Bielschowsky staining they are commonest in the second and third cortical layers (Duyckaerts et al.,

1986; Pearson et al., 1985). Using Campbell's silver technique, Braak, Braak and Kalus (1989) studied the occipital isocortex in 18 AD patients and observed also a laminar distribution of SP with layers II and III being the most affected. They also pointed out that the cortex covering the depth of the sulci generally shows a larger number of plaques than the cortex spreading over the crest of the gyri. Beach and McGeer (1992) analyzed the distribution of SP in the primary visual cortex (area 17 of Brodmann). They also found a laminar distribution of the lesions with a significant aggregation of plaques at the interface of layers IVc and V, and prominent diffuse deposits within layers I and IVc. In addition to these observations, it has been reported that in cortical areas where the accumulation of beta-amyloid protein is relatively sparse, the deposits tend to show a columnar arrangement, which might be related to the columnar organization of the cerebral cortex (Akiyama et al., 1993).

Amyloid fibrils in plaques and congophilic angiopathy are composed of a 4-Kd protein referred to as the beta-amyloid protein. Other constituents identified within the amyloid core include alpha 1-antichymotrypsin, sulfated glycosaminoglycans, complement factors, and aluminosilicates. The beta-amyloid protein consists of 42 to 43 amino acid residues, with a hydrophobic region of 14 residues (positions 29 to 42) that renders the peptide insoluble. Molecular cloning studies have

determined that the beta-amyloid peptide is a truncated form of a much larger protein called amyloid precursor protein (APP). The arrangement of amino acids in the APP suggests that it has one membrane-spanning segment, a large extracellular amino-terminal region, and a shorter intracellular carboxy terminus. The beta-amyloid peptide encompasses 14 amino acids of the putative transmembrane domain and 28 amino acids of the adjacent extracellular domain of APP (Kang et al., 1987; Koo and Price, 1993; Selkoe, 1991; Tomlinson, 1992).

At least four species of APP messenger ribonucleic acids (mRNA), encoding 563, 695, 751, and 770 amino acids respectively, have been identified. The APP-751 and APP-770 molecules are identical to APP-695 except that they contain a domain that shares homology with the so-called Kunitz type of protease inhibitors, which could play a fundamental role in the generation of beta-amyloid protein (Ponte et al., 1988; Tanzi et al., 1988; Tanzi, St George-Hyslop and Gusella, 1989). APP-695 mRNA is expressed predominantly in the nervous system, whereas APP-751 and APP-770 transcripts are expressed both in brain tissue and systemic organs. Currently little is known about the shortest APP transcript (APP-563), which lacks the membrane domain (Koo and Price, 1993).

Recent reports have determined that in culture systems a natural cleavage of the APP molecule occurs near the middle of the beta-amyloid domain, which suggests that normal processing

of APP precludes the formation of an intact amyloidogenic fragment. As a result, amyloidogenesis presumably requires the absence of this normal cleavage event and might be the result of an aberrant processing of the APP molecule (Gandy and Greengard, 1992; Koo and Price, 1993; Mattson et al., 1993; Selkoe, 1991).

The physiologic roles of APP are not known, and neither is the part played by the beta-amyloid protein in the pathogenesis of the disease. A trophic or autocrine property of APP has been suggested. This hypothesis is in accord with the discovery that the APP with the Kunitz domain is a specific cell secreted protease inhibitor (protease nexin II), capable of forming complexes with epidermal growth factor-binding protein and the gamma subunit of nerve growth factor. In addition, protease nexin II is a potent inhibitor of chymotrypsin, a fact that could have some relevance, considering that previous works have suggested the involvement of a chymotrypsin-like protease in the deposition of beta-amyloid protein (Oltersdorf et al., 1989; Van Norstrand et al., 1989).

Mattson and co-workers (1993) have suggested that APP is involved in calcium homeostasis. According to them, normal enzymatic processing of APP results in the liberation of secreted forms of APP which presumably bind to and activate specific cell surface receptors on target cells. This

activation would cause a reduction in intracellular calcium levels and would protect against aberrant rises that can occur when neurons are subjected to adverse conditions (e.g., ischemia, trauma, excitotoxins). The abnormal processing of APP, then, would have two major consequences for neurons. First, the normal intracellular calcium-stabilizing and neuroprotective function of APP is compromised. Second, beta-amyloid peptide aggregates and further destabilizes calcium homeostasis.

Recently, Nishimoto et al. (1993) proposed a novel possibility: APP is a neuronal receptor coupled to Go (a major GTP-binding protein in the brain) and abnormal APP-Go signalling is involved in the pathogenesis of AD. They suggested that after the proteolytic release of the beta-amyloid fragment, the residual C-terminal portion of APP may remain in the cell membrane and could injure neurons through constitutive stimulation of a cell signalling pathway involving Go.

In vitro studies with dissociated hippocampal neurons have shown that beta-amyloid fragments seem to be neurotrophic to immature neurons but neurotoxic to mature neurons (Yankner, Duffy and Kirschner, 1990). Malouf (1992) observed degenerative changes after the application of the whole beta-amyloid protein to cultured neurons, but failed to demonstrate any neurotoxicity using beta 1-28 or beta 25-35 fragments.

However, Pike et al. (1993) reported neurodegeneration induced by different beta-amyloid fragments, but their most significant result was that toxicity was associated specifically with those peptides that exhibited significant aggregation. Another recent in vitro study (Carpenter, Crutcher and Kater, 1993) analyzed the effect of SP on living neurons using cryostat sections from the cerebral cortex of Alzheimer patients as a substratum for cultured rat hippocampal neurons. The authors concluded that SP can have deleterious effects on neuronal organization in situ, affecting the amount, complexity and direction of neurite outgrowth as well as cell survival.

The results of in vivo studies have been more contradictory. Various groups have observed no significant morphological difference after beta-amyloid fragment injections, as compared to vehicle control injections in rat or rhesus monkey brains (Games et al., 1992; Podlisny et al., 1992; Stein-Behrens et al., 1992). On the other hand, there are reports of significant toxicity of beta-amyloid and the beta 25-35 fragment intracerebrally injected in the same species (Emre et al., 1992; Kowall et al., 1992). Methodological variations could account for some of the differences, but in general it seems that the simple intraparenchymal injection of beta-amyloid is not a good model for the study of Alzheimer-related neurotoxicity.

The origin of the beta-amyloid peptide that accumulates in SP and in the wall of blood vessels is controversial. Two prevailing hypotheses, not mutually exclusive, argue for neuronal and vascular origins. Evidence for a neuronal origin has been given by the topographic distribution of SP within the gray matter; the neuronal localization of APP mRNA, including high levels of APP-695; the transport of APP in axons; the localization of N- and C-terminus of APP in neurites surrounding amyloid deposits; and the finding of beta-amyloid deposits adjacent to neurites in plaques (Koo and Price, 1993).

Evidence for a vascular origin includes the proximity of blood vessels to SP; deposits of amyloid in meningeal vessels outside the brain parenchyma; the presence of full-length APP molecules in platelets; the presence of serum components (e.g., complement factors) in amyloid; the possible increased permeability of the blood-brain barrier in aging; and the presence of beta-amyloid immunoreactivity in the skin of individuals with AD (Koo and Price, 1993).

These two hypotheses; however, do not exclude the possibility that the deposition of amyloid in brain parenchyma and in wall of blood vessels may be the result of two independent processes that arise from different compartments of the brain (Rozemuller et al., 1993).

1.2.3) Neurofibrillary tangles

Although NFT are a major histopathological hallmark of AD, other conditions exhibit variable degrees of NFT formation. These include normal aging, aged individuals with Down's syndrome, dementia pugilistica, the Parkinsonism-dementia complex of Guam, postencephalitic Parkinsonism, and subacute sclerosing panencephalitis (Wisniewski et al., 1979).

With silver stain they appear as fibrillary structures within perikarya, but their configuration may vary according to the site of the tangle, the type of neuron affected, and the stage of its development (Baner et al., 1989; Vickers, Delacourte and Morrison, 1992). In most cells with NFT the nucleus can still be identified, but sometimes, presumably in the final stages, the cell outline disappears and only the distorted fibrils remain in the neuropil, giving rise to what have been called "ghost tangles" (Koo and Price, 1993; Tomlinson, 1992).

Recently, a new type of lesion has been described in relation to "ghost tangles" (tangle-associated neuritic cluster), in which abnormal neurites form dense aggregates, each centered by an extracellular (ghost) tangle instead of by an amyloid deposit (Munoz and Wang, 1992). Tangle-associated neuritic clusters were abundant in the hippocampus of all AD cases analyzed by these authors (n=14), and a few could be

found in the nucleus basalis of Meynert and occasionally in the neocortex. Similar lesions were reported by Ikeda et al. (1992) in the hippocampus of AD patients under the term "degenerative neurite-bearing ghost tangles", but they were found only in 13 out of 30 patients (43%).

Electron microscopy has revealed that the NFT of AD consists of dense bundles of long, unbranching filaments that measure approximately 20 nm across, with a regular constriction to 10 nm occurring every 80 nm. Wisniewski, Narang and Terry (1976) suggested that NFT were constituted by paired filament wound in a double helix (paired helical filaments), a view that has been largely accepted since then. However, although the great majority of tangles found in normal aging and in AD consist predominantly of paired helical filaments (PHF), some authors have described also straight filaments (Shibayama and Kitoh, 1978; Yagashita et al., 1981) and straight tubules (Gibson, Stones and Tomlinson, 1976) in NFT.

NFT occur more in the anterior frontal and temporal cortex than in the posterior parts of the hemispheres, and the pre- and post-central gyri and the primary sensory areas of the cortex are usually little involved. Some categories of cells are particularly resistant and Purkinje cells, Betz cells, and large motor neurons appear to escape almost entirely (Arnold et al., 1991; Pearson et al., 1985).

In normal old age and in AD the heaviest density of NFT is found in the anteromedial temporal cortex, including the uncus cortex, the corticomedial part of the amygdaloid nucleus, the hippocampus and the adjacent parahippocampal gyrus. Tomlinson, Blessed and Roth (1968) and Tomlinson and Kitchener (1972) observed tangle formation in these areas in about 5% of normal people dying in their 40s; the figure increased to 50% for people dying in their 70s, and by the 90s all cases showed some affected neurons. Although there is agreement about the increase in tangle formation that occurs in non-demented individuals throughout middle and late life, quantitative estimations have demonstrated a significant difference in the number of affected hippocampal pyramidal cells in AD compared with intellectually normal persons of the same age (Ball, 1977; Tomlinson, Blessed and Roth, 1970). NFT are also abundant in neocortical areas in AD patients, but in a significant proportion of older cases they can be very scarce or not present at all (Braak and Braak, 1990a; Terry et al., 1987).

Neurons in the subcortical regions can be also affected in AD. NFT are common and sometimes numerous in the basal nucleus of Meynert, the periventricular tissues along the wall of the III ventricle, the septal nuclei, the periaqueductal gray matter of the midbrain, the raphe nuclei and the locus coeruleus (Koo and Price, 1993; Tomlinson, 1992).

The insolubility of PHF has frustrated numerous attempts at purification, and identification of the chemical components has been difficult. Nevertheless, recent evidence suggests that NFT represent sites of cytoskeletal disruption. Immunocytochemical studies have identified several cellular constituents within NFT, including microtubule-associated proteins (MAP2 and tau), A68 (a 68-kd protein, probably a highly modified form of tau, enriched in AD brains and cerebro-spinal fluid and originally identified with the ALZ-50 antibody), neurofilaments (particularly phosphorylated epitopes), and ubiquitin (a protein implicated in the non-lysosomal breakdown of shortlived and abnormal proteins) (Cork et al., 1986; Grundke-Iqbal et al., 1986; Kosik et al., 1984; Kosik, Joachim and Selkoe, 1986; Lee et al., 1991; Perry et al., 1987; Wolozin and Davies, 1987).

PHF are also present in dystrophic neurites of SP and in "neuropil threads", which are thickened and twisted argyrophilic cell processes dispersed in the neuropil between SP and NFT. Braak and Braak (1988) and Ihara (1988) have produced evidence that neuropil threads are the result of massive dendritic sprouting of cortical neurons involved in NFT formation, and Duyckaerts et al. (1989) reported a correlation between the number of these abnormal fibers and the severity of dementia.

Identification of neurons forming NFT prior to actual

accumulation of PHF has not been successful. Tabaton et al. (1988) suggested that the monoclonal antibody ALZ-50 may well detect such neurons, since it immunostains neurons both with and without tangles.

In the normal brain, tau is most abundant in axons where it is not phosphorylated, although low levels of phosphorylated tau are also present in the cell bodies and dendrites. Accumulation of larger quantities of phosphorylated tau in somatodendritic compartments, as detected by anti-tau antibodies, is one of the earliest identified abnormalities in AD and occurs prior to the formation of PHF (Banerjee et al., 1989). Phosphorylated tau is less effective in microtubule assembling; as a result, tau may not properly associate with tubulin and free tau may co-assemble into PHF (Montejo de Garcini et al., 1988).

Another probable marker is MAP5, an early form of microtubule-associated proteins that is normally expressed during the developmental growth of neurons. Aberrant MAP5 expression has been observed in the hippocampus of AD patients (Geddes, Lundgren and Kim, 1991), but in contrast to tau alterations, which are observed primarily in neurons with a predilection for AD pathology, MAP5 immunoreactivity has been observed in both vulnerable and non-vulnerable hippocampal neurons. It is therefore uncertain whether the alterations in MAP5 immunoreactivity precede or occur in response to the AD

neuropathology.

Despite considerable progress made during the last decade in understanding the molecular pathology of NFT and the amyloid fibrils of SP, the problem of their relationship remains unsolved.

Masters et al. (1985) proposed that amyloid fibrils in SP and in blood vessels were related to intraneuronal PHF and that all three fibrous deposits were composed of the same protein, but Selkoe et al. (1986) observed that the amyloid core of SP was not immunostained using polyclonal and monoclonal antibodies that label PHF, including anti-tau antibodies.

For many years, a number of diseases have been characterized by NFT formation in the absence of plaques. The Parkinsonism-dementia syndrome of Guam, dementia pugilistica, subacute sclerosing panencephalitis, progressive supranuclear palsy, and postencephalitic Parkinsonism are well known examples. It has been recently shown, however, that at least in some cases of progressive supranuclear palsy and dementia pugilistica, diffuse plaques can be readily demonstrated (Roberts, Allsop and Bruton, 1990; Tan et al., 1988). A reverse situation is observed in about 30% of AD patients aged more than 74, in whom absence of neocortical tangles in the presence of numerous SP has been reported (Terry et al., 1987).

Light and electron immunocytochemical analyses of the brains of patients with subacute sclerosing panencephalitis (SSPE), AD and age-matched controls (Tabaton et al., 1989) revealed that abnormal neurites in SSPE were identical to the widespread abnormal neurites of AD, but they occur in the absence of amyloid deposits. They also observed that the distribution of the neuritic alteration correlated with that of NFT in both conditions, but not with that of SP in AD. The authors suggested that their results are consistent with the hypothesis that in AD the widespread alteration of neuronal processes is not secondary to the deposition of amyloid.

The reports of Probst et al. (1988, 1989) have shown a differential pattern of immunoreactivity of SP neurites depending on the presence or absence of NFT in the neocortex. In patients with NFT, the neurites of SP were positive for anti-PHF and anti-tau antibodies, but in AD patients with only neocortical SP, the neurites were devoid of immunoreactive material. These findings indicate that PHF and tau polypeptide are not essential components of SP, suggesting that the development of SP in the neocortex may occur independently of PHF pathology of neocortical neurons.

1.3) Neuropsychopathology of cardiovascular diseases

The relationship between cardiovascular diseases and their pathological effects on the central nervous system is very complex, and some areas of this field have not been studied extensively enough. The most frequent neurological complication of cardiac disease is the cardiogenic brain embolism, that arises when embolic material from the heart occludes a brain artery producing stroke. Some studies (Cerebral Embolism Task Force, 1986; Foulkes et al., 1988) have shown that about 15% (range 6% to 23%) of all ischemic strokes are cardioembolic.

The list of cardiac disorders capable of producing brain emboli is extensive (Helgason and Sherman, 1989), but atrial fibrillation with or without associated ischemic or hypertensive heart disease, acute and chronic ischemic heart disease, and valvular heart disease (both rheumatic and prosthetic) are the most frequent types of heart diseases causing cardiogenic strokes.

Research in this field has been very active, partly due to the devastating effects that strokes have on patients' lives. However, apart from their embolic effects, less is known about the cerebral response to altered cardiac rhythm, cardiac ischemia, cardiac failure, and hypertension, which may lead to subtle psychological changes and focal neurological deficits.

Kurosawa and co-workers (1983) studied a group of 163 patients with acute myocardial infarction who were admitted to a Coronary Care Unit during a period of two years, and found that about 64% of all the patients showed some mental disorders, which were considered to be mild or moderate in most of the cases. Anxious and depressive states were the disorders most frequently found, with 42 and 30 affected patients, respectively. They also observed that about 26% of the subjects were in need of psychotropic medication, and about 10% showed disorientation or cloudy consciousness. Furthermore, it has been reported that depression is commonly manifested in patients with serious cardiac diseases and has been noted in many cases to predate the diagnosis of the cardiac abnormality (Tresch et al., 1985).

Another paper (Reich et al., 1983), reporting on a series of six long-term survivors of cardiac arrest, showed that this group of patients may suffer from mild cerebral dysfunction, manifested primarily by personality changes and behavioral symptoms that can be mistaken for emotional responses to illness (depression in most of the cases). The authors suggested that the presence of chronicity, dysinhibition, apathy, and disturbances of judgement and insight are indicative of cerebral dysfunction.

In the last few years, central nervous system complications observed in coronary artery bypass graft (CABG)

surgery have attracted the attention of various research groups, mainly because CABG is the most frequently performed cardiac surgery in North America and due to the fact that central nervous system complications (stroke and encephalopathy) account for the major adverse sequelae of this procedure (Brillman, 1993).

In a retrospective study of 1669 patients who survived this kind of surgery, Coffey et al. (1983) found a central nervous system complication rate of 3.8%, including altered mental state, stroke, and seizures, with a mortality of approximately 30% in patients with neurological complications. A later prospective analysis (Shaw et al., 1985) showed a complication rate as high as 61% in the early postoperative period. In addition to altered mental state, seizures and stroke, the authors also reported the presence of ophthalmologic abnormalities, primitive reflexes, psychoses, depression, and some peripheral disorders, such as brachial plexopathy.

A later study of the same group (Shaw et al., 1987) compared the neurological complications in patients undergoing CABG surgery with a group of matched patients who underwent surgery for peripheral vascular disease not associated with bypass. The authors found that the patients who underwent CABG surgery had a complication rate more than twice as high as that of patients who had peripheral vascular arterial surgery,

implicating bypass as a significant factor in the development of neurological complications.

It seems also that a substantial number of patients have minor cognitive impairment after CABG procedures. According to Newman and co-workers (1990), these abnormalities may occur in up to 75% of patients eight days postoperatively, and may be present in about one-third of patients even one year after surgery. Psychiatric disturbances are also common following CABG surgery. These include agitation, delusions, paranoia, nightmares, sleep disturbances, depression and anxiety, most of which are associated with cognitive deficits (Heller and Kornfeld, 1986).

Over the years some reports have also suggested that hypertensive patients show a poorer performance in various cognitive, perceptual, and psychomotor tasks when compared to normotensive controls, although the deficits are subtle and require sensitive psychological tests for detection (Battersby et al., 1993; Boller et al., 1977; Franceschi et al., 1982; Goldman et al., 1974; Miller et al., 1984). Some studies have indicated that the disease process itself is responsible for these behavioral deficits (Franceschi et al., 1982; Miller et al., 1984), while others have shown impaired functioning with antihypertensive drugs (Lasser et al., 1989; Lichter, Richardson and Wyke, 1989).

These behavioral changes are accompanied and probably

related to a variety of morphological brain changes, but only in the last decade, with the help of more accurate quantitative methods, it has been possible to demonstrate them.

Many studies have been done on spontaneously hypertensive rats (SHR), comparing them with age- and sex-matched Wistar-Kyoto (WKY) rats, the normotensive control strain for SHR. Lehr, Browning and Myers (1980) were the first to report quantitative differences in brain size between SHR and WKY rats. They studied 8-month-old animals and found that the thickness of the pons and overlying cerebellum was greater in SHR than WKY rats, but that the length of the pons, midbrain and diencephalon was less in SHR than WKY rats. Nelson and Boulant (1981) observed that in 12-week-old male SHR total brain weight and volume were about 11% less than in control animals.

The studies conducted by Ritter and Dinh (1986) and Ritter et al. (1988) showed that the ventricles of SHR were enlarged from 8 to 56 weeks of age, but this ventricular dilatation was not diminished appreciably by maintaining lower arterial blood pressure by captopril administration. Furthermore, they reported that the cerebral ventricle cross-sectional area was normal in Sprague-Dawley rats made hypertensive by removing one kidney and partially clipping the renal artery on the other side. They suggested that

ventricular dilatation in hypertension may be genetically linked to the elevation of blood pressure but not driven by it.

Bendel and Eilam (1992) assessed ventricular volumes in vivo in SHR and WKY rats using magnetic resonance imaging. At 2.5 months of age, the ventricular volumes were identical in the two strains. By 3 to 5 months, mean ventricular volume was significantly larger in SHR than WKY rats (37.5 mm³ vs 28 mm³), and by 6 to 8 months the difference was even greater (58 mm³ vs 33 mm³).

A more recent report (Tajima et al., 1993) based on a morphometric study of 6 to 7-month-old SHR and WKY rats showed that ventricular volume was twofold greater in SHR than control rats. The volumes of the entire brain and of all the gray matter structures studied (substantia nigra, periaqueductal gray matter, inferior and superior colliculi, caudate-putamen, and thalamus), and the thickness of the frontal and temporal cortex were 11% to 25% less in SHR. Neuronal frequency was similar in the two rat strains, but having smaller brains, SHR had fewer neurons per brain structure than control rats.

In humans, the results reported so far have shown subtle but definite alterations that might account for some of the cognitive and behavioral changes previously described, and seem to correspond with the data obtained from animal models.

A recent in vivo study (Salerno et al., 1992) of 18 carefully selected long-term hypertensive patients and 17 control subjects, using magnetic resonance imaging, showed that the hypertensive patients had significantly larger volumes of the right and left lateral ventricles and a significantly smaller left hemisphere volume (normalized to intracranial volume).

The work carried out by a group of researchers at the University of Kentucky Medical Center (Sparks et al., 1990) brought about a previously unrecognized relationship between critical coronary artery disease (CCAD) and the presence of SP in the brain. They studied the brains (frontal pole, hippocampus and parahippocampal gyrus) of 20 non-demented subjects dying as a result of CCAD or having CCAD as an incidental finding at autopsy, 16 non-demented, non-heart disease subjects, and 17 individuals with clinical manifestations and pathological confirmation of AD. Their results indicated that SP formation was abundant in the brains of patients with CCAD compared to the brains of control subjects. Furthermore, there was a significantly greater prevalence of SP in the CCAD group: 15 out of 20 CCAD patients had SP, but they were only present in 2 out of 16 control cases.

A more recent report of the same group (Sparks et al., 1993) corroborated these results using a larger sample (104

CCAD subjects and 91 controls). In addition to having a significantly greater prevalence of SP than non-heart disease subjects, CCAD patients also had a greater prevalence of neuropil threads and all of them showed ALZ-50 immunoreactive neurons in the parahippocampal gyrus. The authors suggested that the sequence of plaque formation is initiated by the presence of ALZ-50 immunoreactive neurons followed in order by neuropil threads, amyloid beta-protein deposition and formation of diffuse SP.

Based on the results of Sparks and co-workers (1990, 1993), the present study has intended to corroborate their observations expanding the analysis to other brain areas, including subcortical structures, and considering not only patients with CCAD , but also hypertensive subjects.

The two main objectives of this work are:

- 1) To determine if the brains of patients with severe cardiovascular diseases (CCAD and/or hypertension) show any sign of SP formation.
- 2) If SP are present, to know how their distribution compares with that of AD patients.

MATERIALS AND METHODS

2.1) Description of the sample

In order to accomplish the objectives previously mentioned, the brains of 40 patients, obtained at post-mortem examination, were studied. This sample was divided into 3 groups, according to the clinico-pathological findings of the individual cases: a cardiovascular disease (CVD) group, an Alzheimer's disease (AD) group, and a control group. All brains were obtained from the Department of Pathology of the Memorial University of Newfoundland, St. John's, Newfoundland.

The CVD group included 17 patients (13 males and 4 females, mean age: 70 years), the AD group comprised 12 patients (4 males and 8 females, mean age: 80 years), and the control group consisted of 11 patients (6 males and 5 females, mean age: 68 years). All individuals were 60 years of age or older. The CVD and control groups were similar regarding age, but AD patients were significantly older than patients of the other two groups. Table 2.1 summarizes the descriptive characteristics of the sample.

With the purpose of studying the effects of different cardiovascular problems, the CVD group was further divided into two subgroups: patients with critical coronary artery disease (CCAD), and hypertensive (HT) patients. The former

TABLE 2.1: DESCRIPTIVE CHARACTERISTICS OF THE SAMPLE

	CVD	AD	Control
n	17	12	11
males	13	4	6
females	4	8	5
age	70.3 +/- 6.9	80 +/- 5.9	68.4 +/- 8.8

consisted of 12 patients, with an average age of 71 years, and the latter included 11 patients with a mean age of 69 years. The descriptive data corresponding to the two subgroups are summarized in Table 2.2. Six out of 17 patients of the CVD group had both, CCAD and HT, and thus were included in both subgroups. The remaining 11 cases comprised six CCAD patients and five HT patients.

The criteria to conform each group were as follows:

Alzheimer's disease group:

- 1) Patients with a clinical diagnosis of dementia.
- 2) Pathological confirmation of AD according to Kachaturian's criteria (Kachaturian, 1985).

TABLE 2.2: DESCRIPTION OF THE SUBGROUPS OF CVD PATIENTS

	CCAD	HT
n	12	11
males	10	7
females	2	4
age	71.6 +/- 7.2	69.6 +/- 6.9

Cardio-vascular disease group:

- 1) Non-demented patients.
- 2) Normal neuropathological examination (no tumor, hemorrhage, infarct, trauma, or evidence of a degenerative disease).
- 3) Clinico-pathological diagnosis of CCAD and/or HT.
- 4) CCAD was defined as more than 75% of occlusion of the right coronary artery, the main trunk of the left coronary artery, the anterior interventricular artery or the circumflex artery. Only patients in whom CCAD was the direct cause of death or one of the principal diagnoses were included. If CCAD was an incidental finding at autopsy, the case was not

considered.

5) Hypertensive patients were included with a clinical diagnosis of HT and the presence of cardiomegaly and/or left ventricular hypertrophy at post-mortem examination.

6) Cardiomegaly was defined as a heart weight of more than 350 g in females and 400 g in males. Left ventricular hypertrophy was considered when the thickness of the left ventricle wall was 15 mm or more.

Control group:

- 1) Non-demented patients.
- 2) Normal neuropathological examination.
- 3) No severe or moderate occlusion of the coronary arteries (less than 50%).
- 4) No clinical history of HT, or cardiomegaly, or left ventricular hypertrophy at post-mortem examination.

The clinical records of all patients were reviewed in order to collect relevant clinical information, especially related with the presence of any signs of dementia.

2.2) Neuropathological assessment

2.2.1) Initial procedures

Following removal, the brains were weighed and fixed in

10% neutral-buffered formalin for at least 7 days. Routine neuropathological examination was carried out after the fixation period. When this examination was finished, samples were taken from different brain areas for the purposes of this study.

The sampled areas were seven and were distributed as follows:

a) In a coronal section at the level of the anterior commissure:

- the left middle frontal gyrus.
- the head of the left caudate nucleus.

b) In a coronal section at the level of the lateral geniculate nuclei:

- the left superior and inferior watershed areas.
- the hippocampal formation with the transentorhinal cortex, which corresponds to the perirhinal area or area 35 of Brodmann (Braak and Braak, 1985).

c) The left primary visual cortex (area 17 of Brodmann), 15 mm anterior to the occipital pole.

d) The anterior lobe of the cerebellum, 10 mm to the right from the midline.

The hippocampal formation was studied in all cases. The middle frontal gyrus was also analyzed in all cases with the exception of two, one AD and one CVD patient. Inferior and superior watershed areas were available in four AD, 11 CVD,

and five control cases. The visual cortex was analyzed in five AD, 11 CVD and five control patients. The caudate nucleus was studied in eight AD, 11 CVD, and six control cases, and the cerebellum in all AD and control cases and in 16 out of 17 CVD patients.

The tissue blocks obtained from these areas were embedded in paraffin and sectioned at 7 micrometers. Sections were mounted on gelatin-coated slides and consecutive sections were stained with cresyl violet, and by the Bielschowsky technique for paraffin sections and the anti-amyloid beta-protein immunohistochemical method.

Cresyl violet-stained sections were used to assess the cytoarchitectural characteristics of the different areas. Sections stained by the Bielschowsky method were employed to study the distribution of SP and NFT as well as for the quantitative assessment of these lesions. Immunohistochemistry for amyloid beta-protein was used also to study the distribution of SP and to compare it with the results of the silver impregnation technique. This method was employed as well to detect amyloid deposition in the walls of intraparenchymal and meningeal blood vessels.

It is useful at this point to make a few comments about the nomenclature used in this study, particularly that regarding the hippocampal formation. For the subregions of the Cornu Ammonis or hippocampus proper we followed Lorente de

No's classification (CA1-CA4) instead of Rose's classification (H1-H5). We have not tried to differentiate the subiculum from the prosubiculum, but we rather have combined the two subregions under the term "subiculum". A similar decision in the rat brain was taken by Blatted (1956) and in the human brain by Casanova et al. (1993).

There has been some confusion in the literature with respect to the cortical areas that make the transition between the temporal isocortex and the hippocampus proper. The cortex bordering laterally the hippocampal formation consists of two regions: Brodmann's areas 28 and 35. In the posterior two-thirds of the hippocampus, which includes the level examined in this study, Brodmann's area 28 is replaced by area 35 which has received a variety of names such as transentorhinal cortex, perirhinal cortex or proisocortex (Braak and Braak, 1985; Casanova et al., 1993).

2.2.2) Staining methods

Cresyl violet (Culling, 1974):

Solutions:

1) Cresyl violet solution:

cresyl violet	0.1 g
distilled water	100 ml

2) Cresyl violet differentiator:

95% alcohol	90 ml
chloroform	10 ml
glacial acetic acid	3 drops

Procedures:

- 1) Bring sections to distilled water.
- 2) Stain in cresyl violet for 10 minutes at room temperature.
- 3) Wash in distilled water.
- 4) Wash in 70% alcohol.
- 5) Differentiate in cresyl violet differentiator for 1 to 2 seconds.
- 6) Rinse in 95% alcohol to remove differentiator.
- 7) Rinse in absolute alcohol and clear in xylol.
- 8) Check differentiation under microscope.
- 9) Mount.

Bielschowsky technique for paraffin sections (Mirra Hart and Terry, 1993):

Solutions:

- 1) 50 ml of 20% silver nitrate.
- 2) Ammoniacal silver solution:

To 50 ml of 20% silver nitrate add concentrated ammonium

hydroxide drop by drop until the precipitate which is first formed has dissolved.

3) Developer:

40% formaldehyde	20 ml
citric acid	0.5 g
concentrated nitric acid	2 drops
distilled water	100 ml

4) Fixative: 5% sodium thiosulfate.

Procedures:

- 1) Take sections to distilled water.
- 2) Preheat 50 ml of 20% silver nitrate for 10 minutes at 56 C and place sections in this solution for 15 minutes in the dark at 37 C.
- 3) Wash in distilled water for 2 minutes.
- 4) Impregnate in the ammoniacal silver solution for 10 minutes in the dark at 37 C.
- 5) Wash in ammonia water (4 drops of concentrated ammonium hydroxide in 50 ml of distilled water) for 2 minutes.
- 6) Add 24 drops of the developer to the coplin jar with the ammoniacal silver solution and leave the sections until the fibers turn black on a yellow background (1 to 3 minutes).
- 7) Wash in fresh ammonia water and then in distilled water for 1 minute.
- 8) Fix in 5% sodium thiosulfate for 2 minutes.

- 9) Wash in 3 changes of distilled water, 3 minutes in each.
- 10) Dehydrate, clear and mount.

Immunocytochemistry for amyloid beta-protein:

Solutions:

- 1) Washing solution:

PBS	200 ml
Triton X	2 ml
normal goat serum	2 ml
- 2) Primary antibody: rabbit polyclonal antibody against amyloid beta-protein (1:50).
- 3) Linking antibody: goat anti-rabbit antibody (1:150)
- 4) Peroxidase anti-peroxidase (PAP) antibody (1:300)
- 5) Diaminobenzidine (DAB) solution:

DAB	50 mg
distilled water	50 ml
0.2M phosphate buffer	50 ml
hydrogen peroxide	33 microliters

Procedure:

- 1) Take sections to distilled water.
- 2) Place sections in concentrated formic acid for 3 minutes (Kitamoto et al., 1987).
- 3) Wash in distilled water for 2 minutes.

- 4) Wash in washing solution for 45 minutes.
- 5) Incubate in the primary antibody overnight at 4 C.
- 6) Wash in washing solution for 20 minutes.
- 7) Incubate in the goat anti-rabbit antibody for 2 hours at room temperature.
- 8) Wash in washing solution for 20 minutes.
- 9) Incubate in the PAP solution for 2 hours at room temperature.
- 10) Wash in washing solution for 20 minutes.
- 11) Place sections in the DAB solution for 3 to 5 minutes and check microscopically, looking for brown staining of the amyloid deposits.
- 12) Wash in PBS.

In order to enhance the results of the immunohistochemistry, a silver intensification method was carried out immediately after the last step described.

Silver intensification method:

Solutions:

- 1) Rinsing solution: 2% sodium acetate.
- 2) 10% thioglycolic acid.
- 3) 1% acetic acid.
- 4) 0.05% gold chloride.
- 5) Fixative: 3% sodium thiosulfate.

6) Physical developer:

Solution A: 5% sodium carbonate.

Solution B:

ammonium nitrate	200 mg
silver nitrate	200 mg
tungstosilic acid	1 g
35% formaldehyde	0.4 ml
distilled water	100 ml

Procedure:

- 1) Wash in 2 changes of sodium acetate, 15 minutes in each.
- 2) Place sections in 10% thioglycolic acid overnight at 4 C.
- 3) Wash in 3 changes of 2% sodium acetate, 15 minutes in each.
- 4) Prepare physical developer adding slowly, while stirring, solution B to solution A (equal parts of each).
- 5) Place sections in the physical developer for 10 to 15 minutes and check microscopically, looking for black staining of the amyloid deposits.
- 6) Stop reaction using 1% acetic acid for 5 minutes.
- 7) Wash in 3 changes of 2% sodium acetate, 5 minutes in each.
- 8) Gold tone (0.05% gold chloride) for 8 to 10 minutes at 4 C.
- 9) Wash in 2% sodium acetate for 5 minutes.

10) Fix in 3% sodium thiosulfate (2 changes, 10 minutes each).

11) Wash in 2 changes of 2% sodium acetate, 5 minutes in each.

After the silver intensification procedure, sections were counterstained with hematoxylin, dehydrated, cleared, and mounted.

In each batch of sections that was processed by immunohistochemistry a control section from an AD patient was included. Negative control sections (incubated without primary antibody) were included in every second or third batch.

2.2.3) Quantification of SP and NFT

Counting of SP and NFT was done on sections stained by the Bielschowsky method. SP were counted in both watershed areas, the middle frontal gyrus, the visual cortex, the transentorhinal cortex, and in 3 areas of the hippocampal formation: dentate gyrus, CA1 region, and subiculum. NFT were counted only in the subiculum and CA1 region of the hippocampus and in the transentorhinal cortex.

In each area SP were counted in 3 fields at X100 magnification, and the mean value of these counts was calculated. In neocortical areas counts were done along cerebral sulci, but not on the surface of the gyri. NFT were

counted in 6 fields at X200 magnification and the mean value of the counts was also calculated.

Sections from the head of the caudate nucleus were evaluated only for the presence or absence of SP, but no quantitative assessment was carried out. Sections from the cerebellum were not quantitatively assessed either. They were used to determine the presence or absence of amyloid deposition and for general neuropathological evaluation.

2.3) Statistical analysis

Mean numbers of SP and NFT were calculated for each of the brain areas previously mentioned in all individuals of the sample in whom the corresponding tissue blocks were available. The SYSTAT statistical package was used for the statistical analysis of the data.

The prevalence of SP and NFT was compared between the CVD group and the control group by using Fisher's exact test. For the purposes of these comparisons, cases were considered positive when they had a mean number of SP or NFT equal to or greater than 1 in at least one of the areas in which these lesions were quantitatively evaluated.

Group mean numbers of SP and NFT were compared by using a one-way analysis of variance (ANOVA) with a post hoc

analysis of inter-group differences by using the protected t-test. Comparisons between CCAD and controls and HT and controls were carried out by using unpaired t-tests (Petrie, 1987).

Results were considered statistically significant when the probability associated with a type I error was less than 5% ($p < 0.05$).

RESULTS

The results of the statistical analysis are summarized in ten graphs. The accompanying microscopic images demonstrate Alzheimer-type histopathology in various cortical and subcortical areas of the brain in AD and CVD patients, as revealed by anti-amyloid immunohistochemistry and the modified Bielschowsky technique.

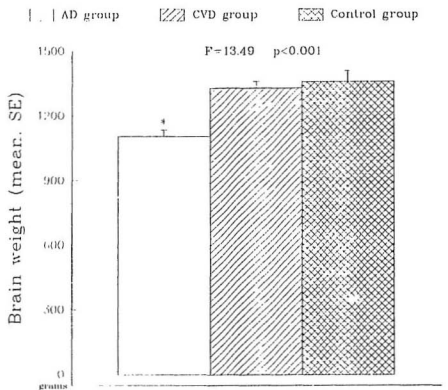
Brain weight in AD patients (1105 g) was significantly lower than in controls and CVD patients (Fig. 3.1). The mean values for the last two groups (1358 g and 1329 g, respectively) did not differ significantly from each other.

According to the Fisher's exact test, there was a significantly greater prevalence of SP in the CVD group as compared to the control group. SP were present in 15 out of 17 CVD patients but only in four of the 11 controls ($p=0.01$). When the prevalence of NFT was considered, the Fisher's exact test did not show significant differences between the two groups. NFT were present in nine out of 17 CVD patients and in three of the 11 control subjects ($p=0.253$).

The analysis of variance revealed that the three groups were significantly different with respect to the number of SP in neocortical areas and the number of SP and NFT in the areas of the medial temporal lobe (Figs. 3.2, 3.3 and 3.4).

When SP were analyzed, the post hoc analysis revealed

Fig. 3.1: Comparison of brain weights.



* significantly different from CVD and Control subjects (p<0.001)

differences not only between the AD group and the other two groups, but also between CVD patients and controls.

In all neocortical areas, SP counts were higher in the CVD group than the control group (Fig. 3.2), but only in the inferior watershed area the difference reached the level of significance ($F=6.91$, $p=0.018$).

The CA1 region was the only area of the hippocampal formation where SP counts were similar and almost null in CVD and control subjects (Fig. 3.3). Among the areas of the medial temporal lobe, the transentorhinal cortex showed the most striking contrast, with mean values of 23.78 and 1.52 for CVD patients and controls, respectively ($F=8.45$, $p=0.006$). The subregions of the medial temporal lobe ranked as follows according to SP density in the CVD group: transentorhinal cortex > subiculum > dentate gyrus > CA1 region.

Post hoc comparisons showed that the AD group was responsible for the differences regarding the number of NFT (Fig. 3.4). In the three areas where NFT were quantitatively evaluated (CA1 region, subiculum and transentorhinal cortex), CVD patients and controls had similar tangle counts, and only those of AD patients were significantly higher.

When only the CCAD patients were considered, the number of SP was significantly higher in the inferior watershed area and the middle frontal gyrus when compared to the control group (Fig. 3.5). The figures were 19.4 vs 0 ($t=3.44$, $p=0.011$)

Fig. 3.2: SP in neocortical areas.

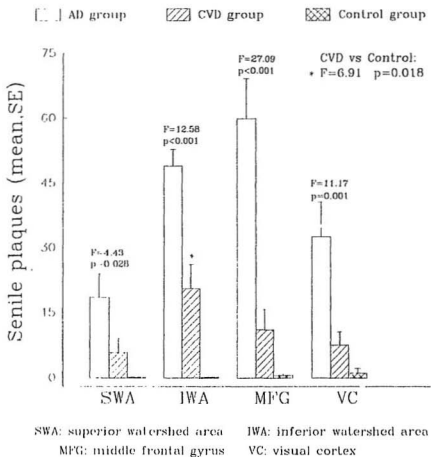


Fig. 3.3: SP in medial temporal lobe.

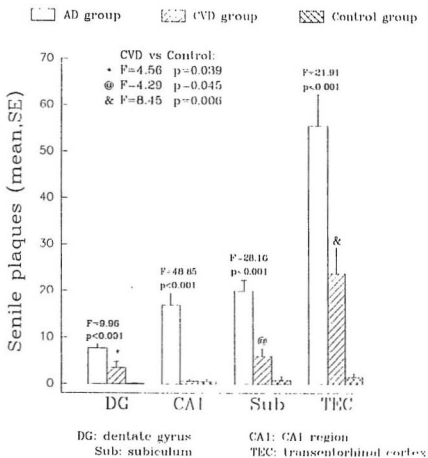
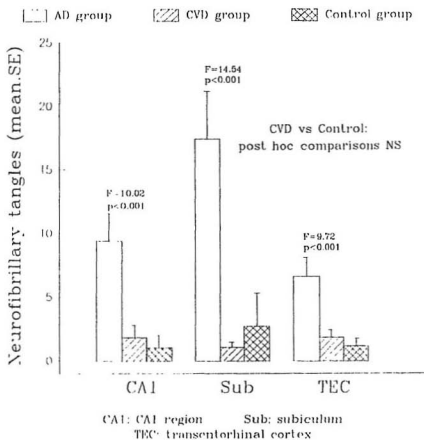


Fig. 3.4: NFT in medial temporal lobe.



for the inferior watershed area and 6.55 vs 0.55 ($t=2.43$, $p=0.036$) for the middle frontal gyrus. In the other two neocortical areas (superior watershed area and visual cortex) the difference did not reach the level of significance.

Figure 3.6 displays the results of comparing CCAD patients and controls with respect to the number of SP in the medial temporal lobe areas. The transentorhinal cortex showed the highest number of SP (23.92 vs 1.52, $t=3.33$, $p=0.0067$) followed by the subiculum (5.17 vs 0.82, $t=2.43$, $p=0.027$). The number of SP in the dentate gyrus was also higher in CCAD patients than controls, but the difference was not significant from the statistical point of view. The CA1 region was almost spared in both groups.

CCAD patients had more NFT than control subjects in the CA1 region and the transentorhinal cortex but in the subiculum the situation was the opposite (Fig. 3.7). These results, however, were not statistically significant.

HT patients were also considered independently. When compared to the control group, HT subjects showed higher SP counts in all neocortical areas (Fig. 3.8) but only in the inferior watershed area the difference was almost statistically significant ($t=2.39$, $p=0.054$). In the other three cortical areas the results did not reach the level of significance.

The transentorhinal cortex of HT patients (Fig. 3.9)

Fig. 3.5: SP in neocortical areas (CCAD).

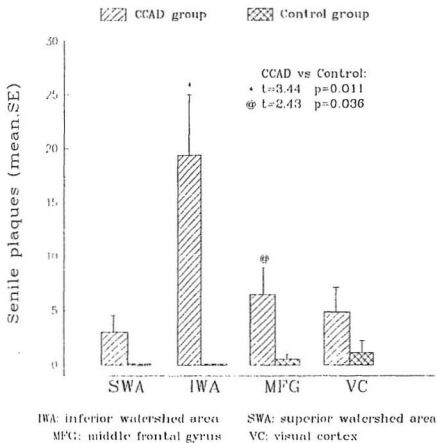


Fig. 3.6: SP in medial temporal lobe (CCAD).

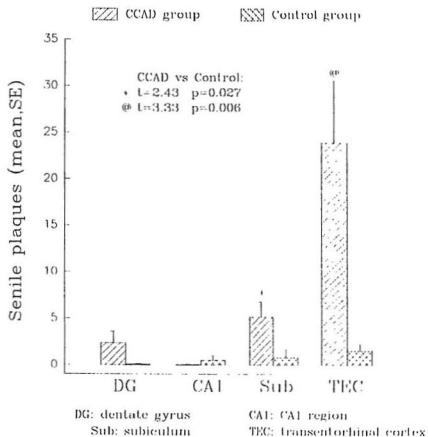


Fig. 3.7: NFT in medial temporal lobe (CCAD).

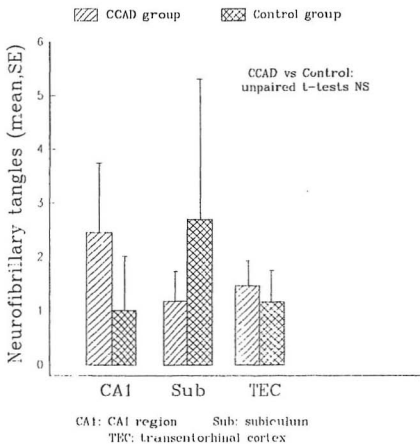
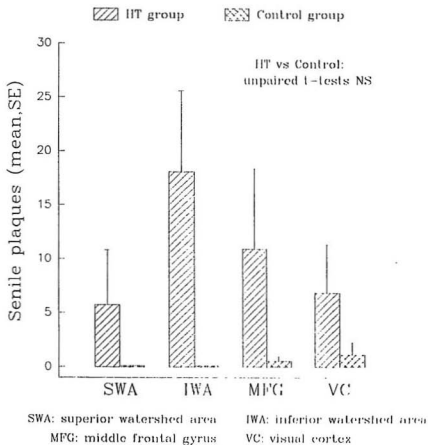


Fig. 3.8: SP in neocortical areas (HT).



showed the most marked and the only statistically significant difference among the subregions of the medial temporal lobe (22.30 vs 1.52, $t=2.88$, $p=0.016$). In the subiculum the result was close to the level of significance ($p=2.06$, $t=0.062$) but that did not occur in the dentate gyrus or the CA1 region. There was no significant difference between HT patients and controls regarding the number of NFT (Fig. 3.10).

Sections from the head of the caudate nucleus and the cerebellum were not evaluated quantitatively but qualitatively. Six out of eight AD patients (75%) showed SP in the caudate nucleus. These lesions, however, were only present in the caudate nucleus of two out of 11 CVD subjects (18%) and were not present at all in the control group. In all AD and CVD cases SP in the caudate nucleus were of the diffuse type.

The cerebellum was affected in nine of the 12 AD patients (75%). Diffuse SP or preamyloid deposits in the molecular layer of the cortex were not the only lesions found. Amyloid (congoophilic) angiopathy, mainly in meningeal arteries, and torpedo-like swellings of the proximal axons of Purkinje cells were also found. The distribution of the cerebellar lesions was as follows: three cases showed diffuse plaques, three cases had amyloid angiopathy, two other cases showed diffuse plaques with torpedo-like swellings and one case had amyloid angiopathy with torpedo-like swellings.

Fig. 3.9: SP in medial temporal lobe (MT).

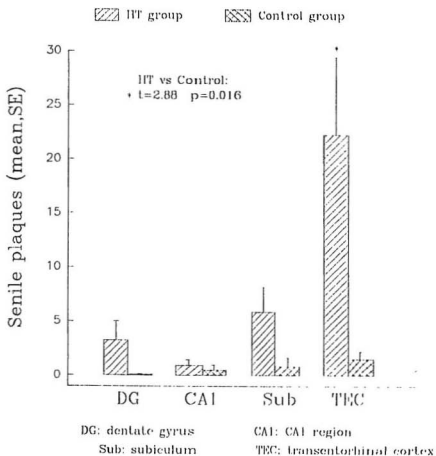
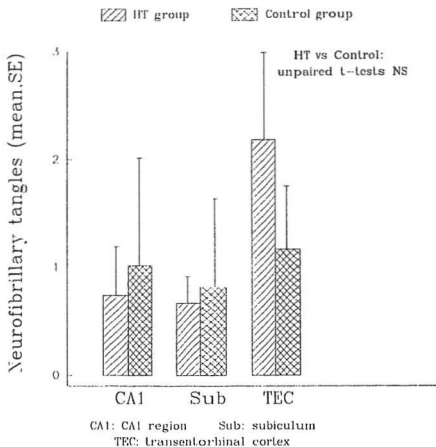


Fig. 3.10: NFT in medial temporal lobe (HT).



In the CVD group the cerebellar lesions were more restricted. Preamyloid deposits were found in the molecular layer of the cerebellar cortex in four patients and a fifth case showed torpedo-like swelling of the axons of scattered Purkinje cells. Preamyloid deposits were also present in the cerebellum of two control subjects.

Deposition of amyloid beta-protein in the walls of blood vessels (amyloid angiopathy) was found in eight of the 12 AD patients (66.7%). Meningeal as well as parenchymal blood vessels were affected. Amyloid angiopathy was present in sections from the frontal, temporal and occipital lobes, and from the cerebellum.

Three CVD subjects had amyloid angiopathy (17.6%) with meningeal and parenchymal distribution. In these three patients the affected vessels were located in the frontal and occipital lobes. Amyloid angiopathy was not found in subjects of the control group.

Microphotographs 3.11 and 3.12 show the two main types of SP found in the brains that were analyzed. Diffuse plaques are seen as ill-defined areas of fine fibrillar material (amyloid beta-protein), while classic plaques consist of a central core of extracellular amyloid surrounded by swollen nerve processes, the so called dystrophic neurites.

Figures 3.13 and 3.14 show two consecutive sections of the dentate gyrus of an AD patient stained by using the

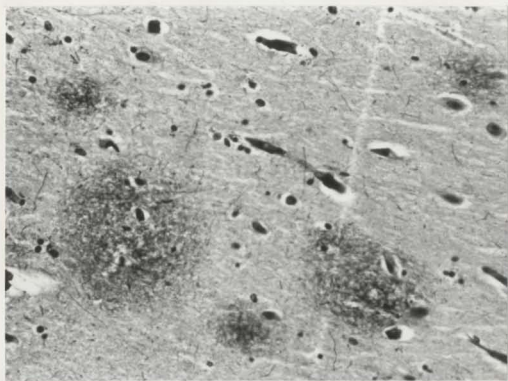


Figure 3.11: Diffuse plaques in the molecular layer of the subiculum of a CVD patient (Bielschowsky, X325 magnification).

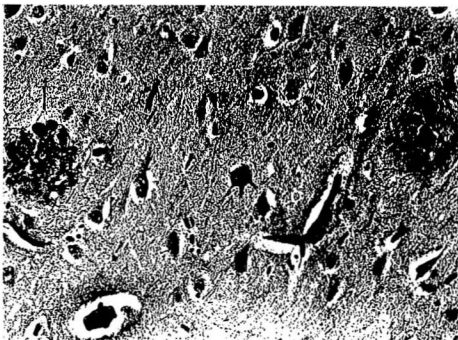


Figure 3.12: Classic plaques in the pyramidal cell layer of the subiculum of an AD patient (Bielschowsky, X325 magnification).

Bielschowsky technique and anti-amyloid immunohistochemistry, respectively. The same SP were demonstrated with both staining procedures. In our experience, the only difference between these two methods is that subpial amyloid deposits (Fig. 3.20) are more easily identified with anti-amyloid immunohistochemistry. This method, on the other hand, required an additional silver intensification in order to improve the contrast of the image.

Figure 3.15 illustrates the distribution of SP in the inferior watershed area of a CVD patient. Almost all the plaques occur in layers II and III, while the deepest layers are almost completely spared. Although the statistical analysis did not show significant differences between CVD subjects and controls regarding the number of plaques in the middle frontal gyrus, ten of 16 CVD patients had a mean number of plaques greater than 1 in this region in comparison with two out of 11 controls. SP in the middle frontal gyrus of CVD patients also predominate in layers II and III of the cortex.

Micrographs 3.16 and 3.17 show the location of SP in the dentate gyrus of AD and CVD patients, respectively. In both groups SP were arranged in an almost linear fashion in the outer part of the molecular layer. The next two illustrations (Figs. 3.18 and 3.19) show some details of SP in the pyramidal cell layer of the subiculum of one AD and one CVD subject. Although the plaques seen in the CVD subject have a few

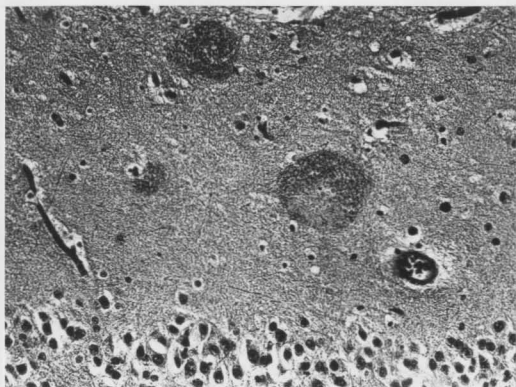


Figure 3.13: Bielschowsky-stained SP in the molecular layer of the dentate gyrus of an AD patient (X325 magnification).

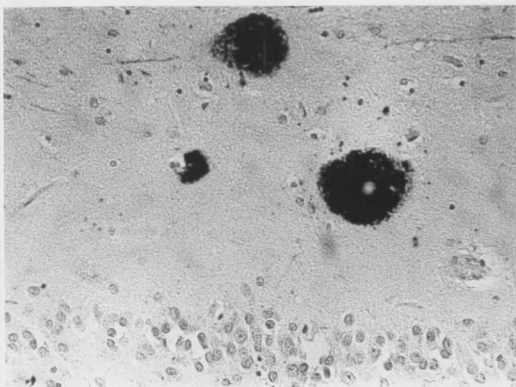


Figure 3.14: Anti-amyloid immunohistochemistry showing the same SP (as in Figure 3.13) in the molecular layer of the dentate gyrus of an AD patient (X325 magnification).

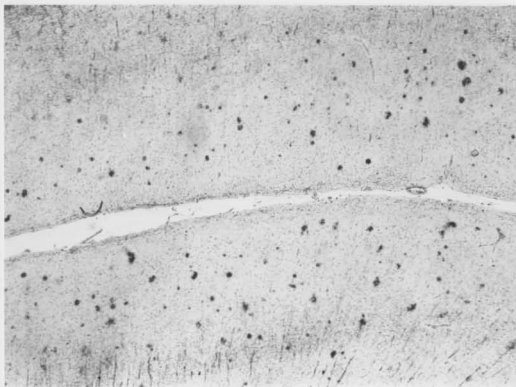


Figure 3.15: SP in the inferior watershed area of a CVD patient (anti-amyloid immunohistochemistry, X65 magnification).

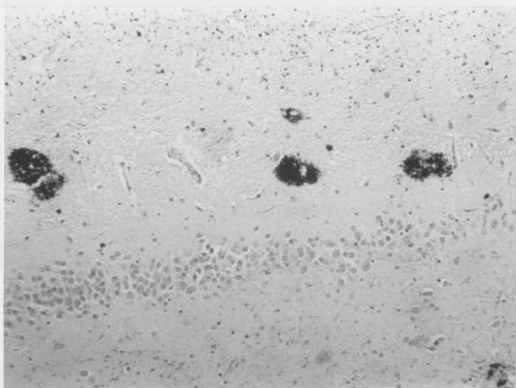


Figure 3.16: SP in the molecular layer of the dentate gyrus of an AD patient (anti-amyloid immunohistochemistry, X162.5 magnification).

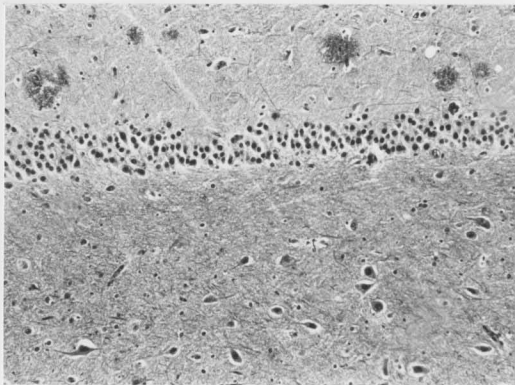


Figure 3.17: SP in the molecular layer of the dentate gyrus of a CVD patient (Bielschowsky, X162.5 magnification).

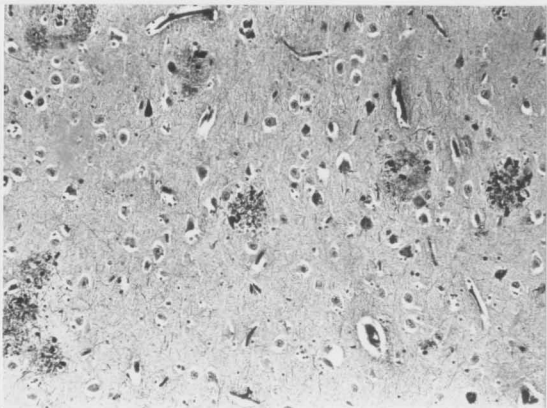


Figure 3.18: SP in the pyramidal cell layer of the subiculum of an AD patient (Bielschowsky, X162.5 magnification).

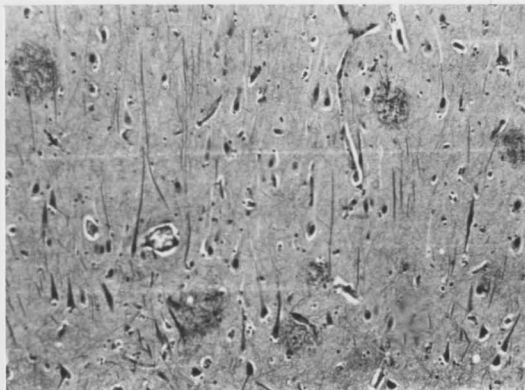


Figure 3.19: SP in the pyramidal cell layer of the subiculum of a CVD patient (Bielschowsky, X162.5 magnification).

dystrophic neurites, these are much more prominent in the classic plaques of the AD patient.

Figures 3.20 and 3.21 demonstrate SP in the transentorhinal cortex. The AD patient (Fig. 3.20) shows widespread SP formation that affects almost the entire cortex. The molecular layer is particularly affected by amyloid deposits that are in general smaller than the plaques seen in other cortical layers. Observe also the presence of subpial amyloid deposits. The transentorhinal cortex of the CVD subject (Fig. 3.21) does not show either subpial deposits or plaques in the molecular layer.

The primary visual cortex of AD patients (Fig. 3.22) shows the greatest number of plaques in layers II and III. There is also accumulation of small plaques in the molecular layer. In addition, two cases showed a significant amount of plaques in layer IVc and a row of plaques at the interface between layers IVc and V. Seven CVD subjects had significant SP formation in the primary visual cortex as opposed to just one control, but there were no statistical differences between the two groups with respect to the number of plaques. In the CVD group most of the SP were of the diffuse type and accumulated in layers II and III of the cortex. Four cases had few SP in layer IVc and the interface IVc-V.

Microphotograph 3.23 represents a section from the head of the caudate nucleus of an AD patient. Diffuse plaques can

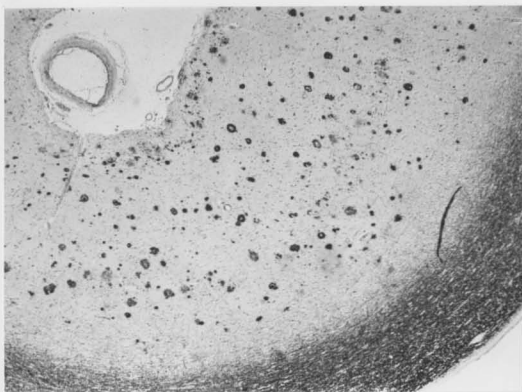

Figure 3.20: SP in the transentorhinal cortex of an AD patient (anti-amyloid immunohistochemistry, X65 magnification).

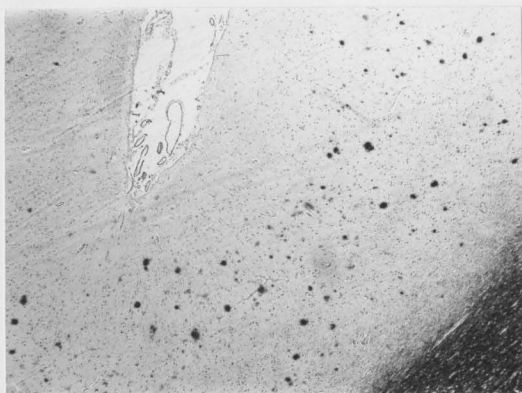


Figure 3.21: SP in the transentorhinal cortex of a CVD patient (anti-amyloid immunohistochemistry, X65 magnification).

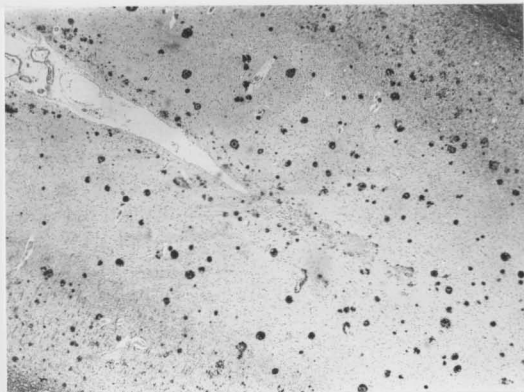


Figure 3.22: SP in the primary visual cortex of an AD patient (anti-amyloid immunohistochemistry, X65 magnification).

be seen in the neuropil, but they do not affect the bundles of myelinated nerve fibres that traverse the nucleus. A narrow zone immediately underneath the ependymal lining of the lateral ventricle was always free of amyloid deposits in the caudate nucleus.

As already mentioned, cerebellar lesions included diffuse plaques in the molecular layer of the cortex, torpedo-like swelling of the axons of Purkinje cells and amyloid angiopathy of meningeal and parenchymal blood vessels. Figures 3.24, 3.25 and 3.26 demonstrate these lesions in the cerebella of AD patients.

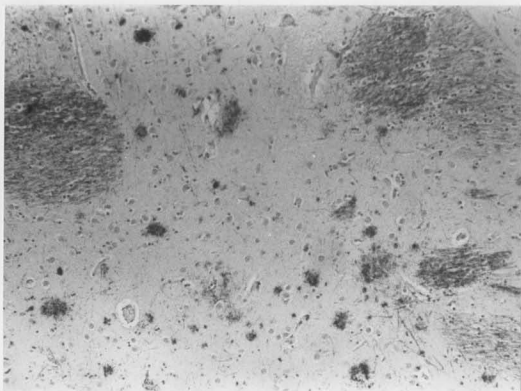


Figure 3.23: SP in the head of the caudate nucleus of an AD patient (anti-amyloid immunohistochemistry, X162.5 magnification).

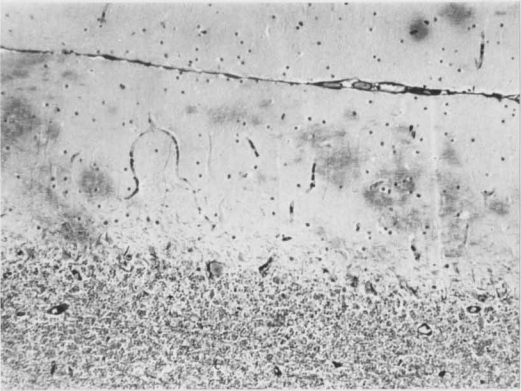


Figure 3.24: Diffuse plaques in the molecular layer of the cerebellar cortex of an AD patient (Bielschowsky, 162.5X magnification).

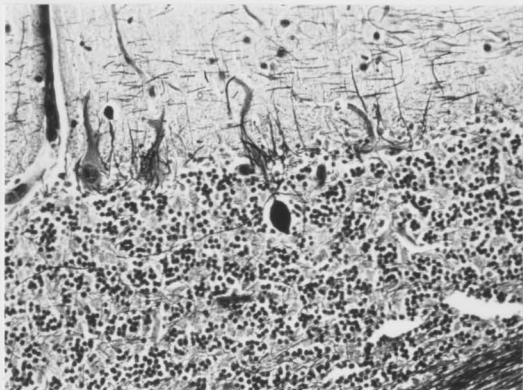


Figure 3.25: Torpedo-like swelling of the axon of a Purkinje cell in the cerebellum of an AD patient (Bielschowsky, 325X magnification).

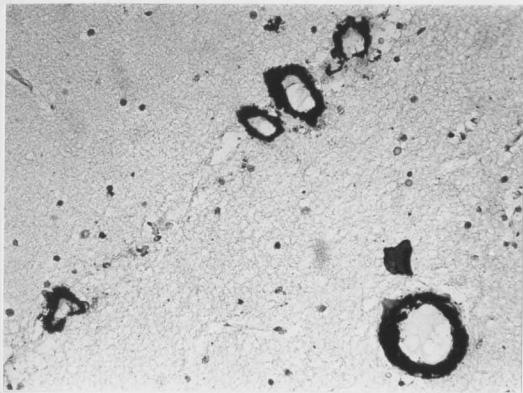


Figure 3.26: Amyloid angiopathy of meningeal and parenchymal blood vessels of the cerebellum of an AD patient (anti-amyloid immunohistochemistry, 325X magnification).

DISCUSSION

4.1) Brain weight

It is well known that the most striking macroscopical finding in AD patients' brains is their atrophic appearance, which is characterized by reduction of the volumes of gray and white matters and dilatation of sulci and ventricles. This atrophy, of course, is reflected by a significant reduction of brain weight (American Academy of Neurology, 1980; Corsellis, 1976; de la Monte, 1989; Tomlinson, 1992).

In our sample of AD subjects the mean brain weight was 1105 gm, which was significantly lower than the brain weights of the CVD and control groups (1329 gm and 1358 gm, respectively). This result agrees with the expected reduction of brain weight in AD patients and represents a decrease of approximately 18% as compared with the other two groups, which is very close to the 20% reduction reported by Koo and Price (1993).

As mentioned before, the AD group was significantly older than the other two groups. This age difference could account for a small percentage of the brain weight reduction observed in AD patients, but we think the disease itself is responsible for most of it.

A detailed analysis of brain weight in 1261 subjects

reported by Ho et al. (1980) showed that the brain mass decreases significantly only after the age of 80 years and in our sample only five of the 12 AD patients were above this age limit. In addition to that, the mean loss of brain weight in old age recorded in a number of investigations (Blinkov and Glezer, 1968; Korenchevsky, 1961) is about 100 gm, but in our study the mean brain weight of the AD group was approximately 235 gm lower than the figures of the other two groups.

CVD patients and controls did not differ from each other regarding brain weight. A similar result was reported by Sparks and co-workers (1990) who found no difference between the brain weights of CCAD and non-heart disease patients, despite the fact that the former group had significantly more SP than the latter one.

4.2) Severe CVD and SP formation

In this study we report the existence of a relationship between severe CVD and the number of SP in the brain. Our results indicate that many non-demented subjects having CCAD and/or HT as a principal pathological diagnosis (post-mortem) have abundant SP formation in different areas of the cerebral cortex. CVD patients showed a higher prevalence of SP than controls and had significantly larger SP counts in the

inferior watershed area, dentate gyrus, subiculum and transentorhinal cortex.

These results agree with the reports of Sparks and co-workers (1990, 1993) regarding SP formation in the brains of non-demented patients dying with or as a consequence of CCAD. They suggest as well that SP formation in CVD subjects is more closely related to the presence of severe cardiovascular alterations than to the existence of a chronic disease. In our sample eight out of 11 control subjects died as a result of chronic diseases and yet their SP counts were significantly lower than those of the CVD group.

It is important to point out that there are some methodological differences between our work and those of Sparks et al. (1990, 1993). Our CVD group included not only patients with CCAD but also HT subjects, while Sparks and co-workers analyzed only CCAD patients (3 of them with concurrent hypertension) but hypertensive subjects without severe occlusion of the coronary arteries were not included in the sample. We considered as CCAD patients only those with a documented clinical diagnosis and CCAD as the cause of death or one of the principal pathological diagnoses, but cases in which CCAD was an incidental finding at autopsy were not included. Sparks et al., on the other hand, included in their CCAD group patients in whom CCAD was an incidental finding at autopsy.

The sampled areas were also different. Sparks and co-workers analysed two cortical areas (frontal pole and parahippocampal gyrus) while our study comprised four neocortical areas (inferior and superior watershed areas, middle frontal gyrus and visual cortex), three regions of the hippocampal formation (dentate gyrus, CA1 region and subiculum), the transentorhinal cortex and two subcortical structures (head of caudate nucleus and cerebellum).

Our results also showed that the distribution and number of SP and NFT was very similar in the two subgroups of CVD patients (CCAD and HT). This is not surprising since it is well known that these two conditions appear together in many patients. In our CVD group, for example, six subjects had both HT and CCAD and for that reason were included in both subgroups. Minor differences found between them are probably the result of analyzing a small sample, although the fact that some subjects were considered in both subgroups could hide the existence of a real difference. We do not think that this is the case, but to elucidate this issue it would be better in future investigations to include patients with only one or the other condition, but not with both.

Because the individuals we studied did not have a formal, detailed psychologic evaluation using psychometric instruments, we cannot exclude the possibility that some of them suffered mild cognitive impairment. However, the criteria

we used for the selection of the sample insured that dementia of a degree sufficient to impair independent living, or to be noted on clinical examination, was not present.

Although the relationship between severity of dementia and SP counts remains controversial, SP formation in the brains of patients with severe CVD might be associated with subtle cognitive and behavioral alterations. In support of this idea, others have shown that 64% of 163 patients exhibited a variety of mental disorders while hospitalized after an acute myocardial infarction (Kurosawa et al., 1983). Reich et al. (1983) observed that long-term survivors of cardiac arrest may suffer from mild cerebral dysfunction. It has been reported also that in many cases depression predates the diagnosis of a cardiac abnormality and constitutes a common manifestation in patients with serious cardiac diseases (Tresch et al., 1985).

In the same line of evidence, it seems that minor cognitive deficit is a relatively common complication after coronary artery bypass graft surgery (Newman et al., 1990; Shaw et al., 1985, 1987). A prospective study (up to 7 years of follow-up) of initially nondemented elderly people showed that history of myocardial infarction was associated with dementia (Aronson et al., 1990). This observation was true for women, so that those with a history of myocardial infarction were five times more prone to dementia than women without a

history, but it was not true for men. A more recent report on risk factors for AD and dementia (Prince, Cullen and Mann, 1994) showed near-significant associations between AD and dementia and several cardiovascular risk factors (electrocardiographic signs of ischemia, systolic hypertension and smoking) among subjects lacking a family history of dementia.

The presence of SP in CVD subjects might be related to very mild behavioral and cognitive alterations, as discussed before. However, according to some studies, this correlation is arguable. Blessed, Tomlinson and Roth (1968) concluded that plaque formation was directly related to the dementing process and could no longer be regarded as a mere epiphenomenon. More recent studies, on the other hand, have found that although SP densities in some cortical areas were still correlated with the severity of dementia, NFT densities showed much better correlations (Arriagada et al., 1992; Berg et al., 1993; McKee, Kosik and Kowall, 1991; Mountjoy et al., 1986; Wilcock et al., 1982). It has been reported also that cognitive impairment is strongly associated with other variables, such as neuronal loss (Neary et al., 1986) and synapse loss (Terry et al., 1991), and that SP counts similar to those found in AD patients can occur in intellectually well preserved old people (Crystal et al., 1988; Katzman et al., 1988).

Two recent studies have failed to demonstrate a relationship between SP counts and the degree of cognitive impairment. Delaere and co-workers (1993) studied 15 non-demented and five demented subjects above the age of 100 years. Amyloid deposits were found in all cases and their density did not correlate with the severity of mental deterioration. Giannakopoulos and co-workers (1993) also analysed the brains of demented and non-demented subjects (7 and 24, respectively) who were between the ages of 96 and 102 years and observed that the density of SP was similar in both groups, with no direct correlation between the number of SP and the presence of dementia.

4.3) Qualitative aspects and staining of SP

Using the Bielschowsky technique for paraffin sections and immunohistochemistry for amyloid beta-protein, the SP found in non-demented CVD patients were similar to the plaques found in AD patients. The differences between the two groups regarding SP were only quantitative, except for the fact that neuritic or "classic" SP were more common in AD patients than in CVD patients. In the latter group the diffuse type of SP was the most abundant. These observations are consistent with those of Sparks et al. (1990), who also measured SP size in AD

and CCAD patients and found no differences between them. They also correspond with previously reported similarities between SP of AD and nondemented elderly individuals (Arriagada, Marzloff and Hyman, 1992; Dickson et al., 1988).

In AD and CVD patients SP were most often observed in the depths of the cerebral sulci rather than on the surface of the gyri. This distribution pattern has been reported previously (Braak, Braak and Kalus, 1989; Sparks et al., 1990; Tomlinson, 1992) and appears to have general acceptance in the literature.

Although we did not perform quantitative comparisons between Bielschowsky- and anti-amyloid-stained sections, our qualitative analysis of consecutive sections stained by the two methods showed that they have very similar sensitivity levels for the detection of SP, with the exception of subpial deposits. These are better shown with immunostaining since the immediate subpial area becomes darker than the rest of the cortex in Bielschowsky-stained sections.

Our results are consistent with the findings of Wisniewski, Wen and Kim (1989) who compared the sensitivity of four staining methods to detect SP, and observed that the Bielschowsky method and immunostaining with formic acid pretreatment were the most sensitive methods showing the highest contrast of plaque image. A similar observation was reported by Braak, Braak and Kalus (1989) who compared the results of

immunohistochemistry for amyloid beta-protein and an enhanced silver technique (Campbell method) in the occipital isocortex.

A recent methodological study (Halliday, Flowers and Baum, 1994) analyzed four methods of tissue processing and revealed that the highest numbers of SP were identified in formalin-fixed, paraffin-embedded tissue regardless of the stain used. They also compared three silver stains and anti-amyloid immunohistochemistry and found that a recent silver method (Garvey et al., 1991), which is considered to be a "modified, modified Bielschowsky", was equivalent to anti-amyloid immunohistochemistry in demonstrating the highest number of plaques.

These authors observed that the modified Bielschowsky silver method revealed the greatest number of plaques, but when they considered the percentage of cortical area occupied by plaques, the result obtained with Garvey's method was significantly higher than that obtained with either Bielschowsky or Bodian. The figures shown by the last two techniques were not different from the statistical point of view, although the percentage of cortical area occupied by plaques as revealed by Bodian was higher than the percentage revealed by the modified Bielschowsky. This result is in disagreement with the work of Wisniewski, Wen and Kim (1989) who considered the Bodian method as being the least sensitive, showing about 26% to 39% of plaques as compared to the

Bielschowsky method.

According to Halliday, Flowers and Baum (1994) plaque identification was easier and more reliable in silver compared to beta-amyloid-stained sections, a result that agrees with our own experience, since we had to use a silver intensification method after the anti-amyloid immunohistochemistry in order to make the plaques darker and to increase the contrast of the images.

Other groups, however, have reported that immunohistochemistry for amyloid beta-protein is more sensitive than silver techniques, so that higher numbers of amyloid deposits can be demonstrated by using it (Beach and McGeer, 1992; Sparks et al., 1993). Despite these controversies, we think that sensitive silver methods are as effective as anti-amyloid immunohistochemistry for the demonstration of SP and make easier their identification. Therefore, we can consider them as reliable methods that can be used for either manual or automated quantification of SP.

Reliable silver techniques are less expensive than immunohistochemistry and most of them stain not only amyloid plaques, but also other lesions that constitute pathological hallmarks for the diagnosis of AD (NFT, neuropil threads and dystrophic neurites of classic plaques). In addition to that, a recent article that intends to be a primer for practicing pathologists (Mirra, Hart and Terry, 1993) suggested the

regular use of either Bielschowsky or thioflavin S methods to make the pathological diagnosis of AD.

4.3.1) Primary visual cortex

Because of its very well defined laminar pattern, the primary visual cortex (striate cortex) has been studied by different groups in order to clarify the laminar distribution of SP in AD patients. The report by Braak, Braak and Kalus (1989) showed that neuritic plaques (SP displaying argyrophilic processes filled with pathological filaments) occur predominantly in layers II and III, while amyloid plaques (plaques containing amyloid, regardless of the presence of abnormal neurites) have a wider distribution, with the more densely stained deposits in layers II, III and IVc. Amyloid plaques in layer IVc were clustered together and form an almost continuous line. A similar aggregation of plaques at the interface of layers IVc and V was reported in AD patients by Beach and McGeer (1992).

We studied the primary visual cortex in five of the 12 AD patients and in all of them the greatest concentration of SP was found in layers II and III. Two of the cases also showed significant accumulation of plaques in layer IVc and its interface with layer V. The population of SP in the striate cortex of AD patients included both diffuse and classic

plaques. In subjects with severe CVD almost all the plaques were of the diffuse type. Only three cases had a few classic plaques. Most of the SP in this group were found also in layers II and III, although four cases (out of 8) showed few plaques in layer IVc and the interface IVc-V. Only one control case had a small number of diffuse plaques in layers II and III.

According to these descriptions, it seems that in the primary visual cortex SP develop first in layers II and III and in a later stage they appear in layer IVc, and particularly at the interface between layers IVc and V.

4.3.2) Caudate nucleus

With the exception of the amygdaloid complex, the rest of the basal nuclei have not been the subject of intensive AD-related research. To our understanding, only few neuropathological studies of the caudate nucleus have been performed in AD patients in the last 10 years (Braak and Braak, 1990b; Oyanagi et al., 1987; Rudelli, Ambler and Wisniewski, 1984).

Oyanagi et al. (1987) analyzed sections of the head of the caudate nucleus and putamen (stained with Kluver-Barrera) from four AD patients and six age-matched control cases. Their results showed a significant decrease in the number of large

neurons with good preservation of the number of small neurons in both caudate and putamen nuclei.

Rudelli, Ambler and Wisniewski (1984) studied thioflavin S-stained material and observed small and rather compact plaques loosely scattered throughout the striatum of AD patients. The more recent study of Braak and Braak (1990b) concluded that the striatum of AD patients and Down's syndrome patients of more than 40 years of age is characterized by an abundance of amyloid deposits (diffuse plaques). Neuritic plaques, on the other hand, were small and occurred infrequently, and amyloid angiopathy was absent.

These authors observed that a narrow zone close to the ependymal lining of the caudate nucleus consistently remained clear of amyloid deposits. This area was also amyloid free in the AD cases of our sample, even in those with a heavily affected caudate nucleus.

Some recent morphometric studies using magnetic resonance imaging have suggested a role of the caudate nucleus in depression. Beats, Levy and Forstl (1991) observed that the radiodensity of the right and left heads of the caudate nuclei was significantly higher in depressed patients, while Krishnan et al (1992) reported that depressed patients had smaller caudate nucleus volumes compared with controls. These results are important if we consider that depression can be seen in approximately 25% of AD patients (Katzman, 1989).

In our study we observed SP in the caudate nucleus of six out of eight AD cases in whom the nucleus was studied. The majority of the plaques were small and of the diffuse type, and only rarely neuritic plaques were found. The development of SP in the caudate nucleus may have some relation with the decrease in the number of large neurons reported by Oyanagi et al. (1987). These lesions could also be involved in the development of depression and extrapyramidal signs in AD patients, the latter ones being considered as an indicator of more rapid deterioration (Stern et al., 1987). Diffuse SP were also present in the caudate nucleus of 2 CVD patients, but their clinical significance is difficult to understand at this point.

We think that the involvement of the caudate nucleus in AD is more extensive than it was thought before. This involvement is particularly important if we consider that the ventral striatum (which includes ventral portions of the caudate nucleus and putamen together with some basal forebrain nuclei) processes limbic system information (from hippocampus, entorhinal cortex, amygdala) destined for the anterior cingulate and medial orbitofrontal areas (Burt, 1993). This points out the necessity for further neuropathological and clinico-pathological studies to clarify the participation of the caudate nucleus in AD.

4.3.3) Cerebellum

For many years the cerebellum was considered to be almost completely spared in AD. Only recently, with the development of more sensitive silver techniques and primary antibodies against amyloid beta-protein, the participation of the cerebellum in the pathological picture of AD has been recognized by many research groups, although its clinical implications await to be clarified.

New research increasingly indicates that the cerebellum coordinates and integrates a wide range of processes not confined to the motor sphere. Gutzmann and Kuhl (1987) studied the relationship of CT-indicated cerebellar atrophy to certain psychopathologic indicators in 39 patients suffering from senile dementia. Their results shown significant correlations between affective incontinency, lability of affect and cerebellar atrophy, but the various indicators of cerebral cortical and subcortical atrophy did not show any strong relationship to affective symptoms at all. The authors suggested the existence of substantial relationships between affective symptoms and cerebellar pathology.

In our study the cerebellum was affected in nine out of 12 AD patients, with diffuse plaques in the molecular layer as the most commonly encountered lesion (5 AD patients, 41.7%). These plaques were seen as areas of fine fibrillar material

with no neuritic involvement. Other findings in the cerebellum included the presence of amyloid angiopathy (4 cases, 33.3%) and torpedo-like swellings of the axons of Purkinje cells (3 cases, 25%).

Braak and co-workers (1989) reported the occurrence of large numbers of amyloid deposits in the cerebellar cortex of demented individuals with complete absence of neurofibrillary changes. The majority of the amyloid deposits were found in the molecular layer. They also observed deposits in the granular layer and white matter, but they were less frequently found and less voluminous. Our study does not confirm the latter finding since we only observed diffuse plaques in the molecular layer, but not in the granular layer or the white matter.

Cole et al. (1989) reported cerebellar amyloid plaques in 31 of 57 AD patients (52%), while Brucher, Gillain and Baron (1989) observed cerebellar amyloid plaques and cerebellar amyloid angiopathy in 80% of 30 brains of demented patients with the histological hallmarks of AD. They also reported that the plaques were not surrounded by swollen neurites and were not immunostained with an antiserum which recognizes kuru-like plaques observed in subacute transmissible spongiform encephalopathies such as Creutzfeldt-Jakob disease and Gerstmann-Straussler-Scheinker syndrome.

Similarly, Joachim, Morris and Selkoe (1989) observed

diffuse plaques in the molecular layer of the cerebellum of 47 of 100 AD patients, with no typical neuritic plaques in this location. Plaques were not recognized by antibodies to neurofilaments, tau and PHF, all of which detect dystrophic neurites in classic plaques. In another study (Suenaga et al., 1990), many cerebellar SP contained ubiquitin-positive granular elements resembling dystrophic neurites, although PHF were not demonstrated with antibodies to phosphorylated neurofilaments or tau proteins. The authors suggested that cerebellar SP were frequently associated with dystrophic neurites.

The results of a recent report (Li, Woodruff-Pak and Trojanowski, 1994) do not support this association. The authors found that amyloid beta-protein deposits in the cerebellum of AD and older Down's syndrome patients only form diffuse plaques. About 65% of these plaques were in physical contact with Purkinje cell dendrites, but neither Purkinje cell bodies nor Purkinje cell dendrites in contact with amyloid deposits showed evidence of structural abnormalities (no immunostaining with primary antibodies to tau, neurofilament proteins, microtubule-associated proteins and ubiquitin).

Yamaguchi and co-workers (1989) also found diffuse plaques in the cerebellar molecular layer in four out of six AD cases, and compact plaques in the Purkinje cell and

granular cell layers in three subjects. In addition, they reported amyloid angiopathy in three of the six cases.

More recently, the presence of amyloid plaques in the cerebellum was observed in 93% of patients who developed dementia before 65 years of age, but this figure dropped to 56% in those patients with dementia beginning after 75 years (Cole et al, 1993). The authors also observed that the severity of the pathological changes in the cerebellum corresponded to the involvement of the brain stem nuclei with connections to the cerebellar cortex.

There are wide variations in the percentages of AD patients with cerebellar amyloid deposits in the consulted literature, which might be related to the age at which dementia appeared (Cole et al., 1993), although most of the studies do not offer any information about the beginning of the symptoms. We were unable to define the beginning of dementia in one of our AD patients, but in the remaining 11 cases the symptoms appeared after the age of 70 years. The lower incidence of cerebellar diffuse plaques observed in this study (approximately 42%), as compared to other reports, may be the result of analysing a sample of AD patients with late onset of dementia.

In certain situations neuronal degeneration is associated with the formation of axonal swellings which are packed with dense bodies, degenerated organelles, filaments or tubules.

During the course of slowly progressive degeneration Purkinje cells of the cerebellum characteristically show an axonal swelling, commonly known as a "torpedo". Torpedoes are present in cerebellar cortical degeneration, a paraneoplastic disease mainly associated with carcinoma of the bronchus, ovary and breast. Degeneration and loss of Purkinje cells with torpedoes on their degenerating axons is widespread in this condition. Torpedoes have been also found in cases of mercury intoxication. In these patients the cerebellar cortex is always affected, with selective loss of granule cells. Purkinje cells are usually spared, although radiating, spiny formations at the end of the dendrites have been described, as well as the presence of numerous torpedoes (Duchen and Jacobs, 1984; Jacobs and Le Quesne, 1984).

In a recent study, Takahashi and co-workers (1992) reported three cases with focal necrotic lesions in the cerebellar white matter and formation of torpedoes. The latter changes were not diffuse, as they are in the above mentioned conditions, but they were essentially confined to the cerebellar cortex overlying the necrotic lesions.

We observed torpedo-like swellings of Purkinje cell axons in three AD and one CVD patient. They were not a striking feature in any of the cases and they were detected only after careful examination of the specimens. Their presence was not associated with loss of Purkinje cells or deposition of

amyloid in the molecular layer. Additional studies are necessary to define the incidence and distribution of torpedoes in the cerebellum of AD and CVD patients and to investigate their pathological significance.

4.4) The hippocampal formation

The predilection of the medial portion of the temporal lobe for the histopathological changes seen both in normal aging and more prominently in AD has been well documented and might even justify special terms such as "limbic dementia" (Hooper and Vogel, 1976) or "hippocampal dementia" (Ball et al., 1985) referring to the latter condition.

Although many authors have commented on the marked involvement of the hippocampus in AD, only a few reports have studied the regional variations of the pathological hallmarks in this area. In 1953, Goodman reported that SP and NFT followed a similar pattern, predominating in the layer II of the entorhinal cortex, subiculum and Sommer's sector (CA1 region according to Barr and Kiernan, 1993; Rose's H1 field according to Ball, 1988). Jamada and Mehraein (1968) gave their rank order as H1, subiculum and presubiculum followed by H2 and H3. Hooper and Vogel suggested that the hippocampus proper was more involved than the entorhinal cortex, while Van

Hoesen and Hyman (1990) reported that SP predominated in the prosubiculum and subiculum as compared with the CA1-4 regions.

A more recent study (Casanova et al., 1993) showed that the rank order for SP in the hippocampus was CA1 = subiculum > CA3/2 > proisocortex (perirhinal or transentorhinal cortex) > CA4. In our study, on the other hand, the incidence of SP in AD patients was as follows: transentorhinal cortex > subiculum > CA1 > dentate gyrus. We cannot comment on the involvement of the CA2-CA4 regions since we did not analyze quantitatively these areas.

From the previous account, it is obvious that the CA1 region, the subiculum/prosubiculum and the entorhinal/transentorhinal cortex are the areas more heavily affected by SP in the medial part of the temporal lobe. Discrepancies in the rank order of these areas are probably the result of methodological differences among the above mentioned studies. These differences include variability in the criteria for patient selection, antero-posterior level of the hippocampal sample, histological techniques used for the demonstration of SP, and nomenclature used.

Some studies have also mentioned the presence of linearly arranged SP along the outer part of the molecular layer of the dentate gyrus (Casanova et al., 1993; Hyman et al, 1984, 1986), a description that perfectly agrees with our observations in that region. This distribution is particularly

significant since the perforant pathway, which originates from neurons in layers II and III of the entorhinal cortex and constitutes one of the major hippocampal inputs, synapses with the most distal portions of the dendritic trees of the granule cells in the dentate gyrus (Burt, 1993).

In the CVD group the distribution of SP in the hippocampal formation was almost similar to that of the AD patients with the exception of the CA1 region, which was almost not affected. The rank order was transentorhinal cortex > subiculum > dentate gyrus > CA1. In the first three areas the density of SP was smaller than in the AC group, as expected, but significantly larger than in controls. It seems that the different cortical areas of the medial temporal lobe are selectively and gradually affected by SP, with the transentorhinal cortex, subiculum and dentate gyrus being affected at an earlier stage than the CA1 region. Significant involvement of the last area is more characteristic of AD brains.

The distribution of NFT in the hippocampal formation of AD patients is by no means random, but rather displays a topographical selectivity as SP do. Goodman (1953) was probably the first investigator to point out this phenomenon. He observed marked involvement with NFT of the large stellate cells of the layer II of the entorhinal cortex and mentioned that other areas affected included the subiculum and Sommer's

sector. Hirano and Zimmerman (1962) observed that the most vulnerable cells of all were those in the glomerular substance of Arnold (layer II of the entorhinal cortex), which they felt showed earlier and more severe involvement even than those of the H1-subiculum. On the other hand, Jamada and Mehraein (1968) reported the H1 field being more affected than the subiculum.

Later on, Ball (1977, 1978) reported the rank order of NFT to be as follows: entorhinal cortex > subiculum > H1 > endplate (H3, H4 and H5). A similar topographical study by Kemper (1978) suggested that both CA1 and subiculum were most heavily affected, followed by Broadmann's area 35 (transentorhinal cortex). Van Hoesen and Hyman (1990) observed that most of the NFT occurred in the subicular/CA1 area, with the parasubiculum being also severely affected. According to these authors, granule cells of the dentate gyrus and pyramidal cells of the CA3/CA4 fields were usually not involved. More recently, Casanova et al. (1993) reported the incidence of NFT to be CA1 > subiculum > CA3/2 > proisocortex > CA4.

All the previously mentioned reports agree in the fact that the CA1-subicular region and the entorhinal cortex are the hippocampal areas more affected by NFT. In our study the rank order of the hippocampal subregions for NFT was subiculum > CA1 > transentorhinal cortex, which supports earlier

observations. We cannot comment on the involvement of the entorhinal cortex since we analysed the hippocampal formation at the level of the lateral geniculate nuclei, which is posterior to it. Although our quantitative study of NFT did not include the dentate gyrus, our observations confirm the lack of involvement of this region.

The mean numbers of NFT in CVD and Control subjects were very low as compared to AD patients and similar as compared to each other. This discrepancy between the distribution of SP and NFT in the hippocampal formation of AD and CVD patients was also reported by Sparks et al. (1990), who observed that NFT were rarely found in either CCAD or non-heart disease subjects and did not exceed the numbers expected in aging.

The presence of abundant SP in the hippocampal formation of CVD patients, with a similar distribution as AD subjects, coupled with the almost complete absence of NFT formation, suggests that these two lesions are not necessarily related to each other, or if there is a temporal relationship between them, the formation of SP, particularly the diffuse type, antedates that of NFT (Coria et al., 1993). It also seems likely that SP alone, at least of the diffuse type, do not disturb hippocampal circuits severely enough to produce significant cognitive changes. NFT, on the other hand, appear to be more strongly correlated with the presence of dementia

(Arriagada et al., 1992; Berg et al., 1993; Mountjoy et al., 1986; Wilcock et al., 1982), which makes them probably better histological hallmarks for the diagnosis of AD.

Braak, Braak and Bohl (1993) have recently proposed a staging of Alzheimer-related cortical destruction based on the hierarchical involvement of specific cortical areas by neurofibrillary changes (NFT, neuropil threads and dystrophic neurites of neuritic plaques). They distinguished six stages which were divided into transentorhinal stages (I and II), limbic stages (III and IV) and isocortical stages (V and VI) according to the spread and severity of cortical destruction. The results of Bancher et al. (1993) showed a strong linear correlation between this neuropathological staging and the intellectual status of aged individuals and Parkinson's disease patients, who were psychometrically evaluated before death.

4.5) Severe CVD and SP: Pathogenetic relationship

The possible pathogenetic relationship between severe CVD and SP formation is unclear. CVD and AD patients may share a common, yet unknown, abnormality, probably related to cardiovascular dysfunction, that leads to the formation of SP. If this is the case, we should find a high frequency of

cardiovascular pathology among individuals with AD. Our study can offer only limited information about this issue. We analyzed the brains of 12 AD patients, but in four of them the autopsy was restricted to the CNS, so that no pathological description of the cardiovascular system was available in these cases. Four of the remaining eight subjects (50%) had severe coronary artery disease, three other cases showed moderate stenosis of the coronary arteries (between 50% and 75%) and the last case had only mild stenosis of the coronary arteries (less than 50%). Although there is a relatively high prevalence of moderate-to-severe coronary artery disease, this sample is too small to draw a valid conclusion. The reports by Aronson et al. (1990) and Prince, Cullen and Mann (1994) have shed some light on this subject, but it is obvious the necessity for additional investigation to determine if cardiovascular pathology is a common occurrence in AD patients.

4.5.1) Blood-brain barrier impairment

The most acceptable explanation connecting severe CVD, AD and SP formation appears to be, so far, the presence of alterations of the blood-brain barrier (BBB). A recent study (Zlokovic et al., 1993) tested whether or not soluble amyloid beta-protein can cross the BBB. The report concluded that the

BBB has the capability to control the cerebrovascular sequestration and blood-to-brain transport of circulating soluble amyloid beta-protein, so that it may contribute to both cerebrovascular and parenchymal amyloid formation.

It has been suggested that SP are closely apposed to small cerebral blood vessels. In a light microscopy study using serial sections stained by PAS, Ishii (1958) observed that 65% to 91% of amyloid plaques were penetrated by or attached to capillaries. Recently Arai et al. (1989) addressed the same issue using beta-protein antiserum, and obtained a similar result.

In 1982 Miyakawa and co-workers studied serial sections of well-developed SP by electron microscopy and observed that all plaques contained at least one degenerated capillary with amyloid fibrils. A more recent report of the same group (Miyakawa et al., 1992) showed that amyloid fibrils were continuous with the basement membranes of pericytes and endothelial cells, suggesting that these fibrils were formed at the basement membranes and extended into the extracellular spaces of the neuropil pushing away the surrounding membranes. This relationship, however, was detected only after detailed examination of many serial sections.

A relationship between the presence of amyloid-rich plaques and cerebral amyloid angiopathy was reported by Mandybur (1975) in 15 AD patients, although no quantitative

analysis was performed in this study. Mountjoy, Tomlinson and Gibson (1982) observed a statistically significant correlation between the amyloid in SP and blood vessels in the temporal lobe in 15 demented subjects. These two studies used Congo red as a marker of SP and blood vessel amyloid. Yamada et al. (1987) examined 123 autopsy brains from aged subjects and demonstrated that the presence and severity of amyloid angiopathy significantly correlated with the density of SP. Another study of 30 AD brains (Bergeron, Ranalli and Miceli, 1987) found no significant correlation between amyloid angiopathy and neuritic plaques, but vascular amyloid and plaque amyloid were significantly correlated.

It has also been reported that in the primary visual cortex, layers II and III and the interface between layers IVc and V show the highest numbers of SP (Beach and McGeer, 1992; Braak, Braak and Kalus, 1989). This result is important for the analysis of SP-microvasculature relationship, because these same layers are the ones that possess the greatest capillary density in the striate cortex (Bell and Ball, 1985).

Contrary to these results, Rosenblum and Haider (1988) reported a negative correlation between the number of congophilic plaques and congophilic vessels. A later immunohistochemical study (Kawai et al., 1990) using different markers for brain microvessels and amyloid plaques concluded that capillaries play only a limited direct role, if any, in

amyloid plaque formation, and that the apparent association of amyloid plaques and capillaries is no more than a chance contact. Independently of the final remarks, the report showed that 60% to 77% of amyloid plaques were in contact with or penetrated by capillaries, and that the border zone area of plaques (10 micrometers rim) had a significantly higher capillary density than the rest of the gray matter.

Delacourte et al. (1987) observed in the temporal and occipital cortex of two patients a morphological relationship between two different Alzheimer lesions: degenerating neurites (marked with a polyclonal antiserum against PHF) and vascular amyloid deposits (stained with thioflavin-S). The authors suggested that the accumulation of PHF-containing neurites around some, always angiopathic vessels, indicates that PHF formation might be a consequence of the primary vascular pathology. They also suggested that these lesions may be comparable to the accumulation of degenerating neurites around the central amyloid core of SP.

Wisniewski and Kozlowski (1982) reported an immunohistochemical study of 12 brains (7 AD and 5 controls) using anti-albumin and anti-globulin antisera. They observed that in areas of the cortex where SP were numerous, all elements of the cortex (especially neurons and reactive astrocytes) and the plaques were heavily stained with both antisera. In control cases only faint staining of the neuropil

and some neuronal perikarya were observed. The authors interpreted their results as an indirect evidence for a change in BBB permeability in AD.

An ultrastructural study of the BBB in humans (Stewart et al., 1987) found no morphological substrate for increased permeability of the BBB (cerebral endothelium) in elderly subjects. The only significant change they reported was a loss of pericytes with age. It has been proposed (Cancilla et al., 1972; Van Deurs, 1976) that these cells act as a second line of defense by phagocytosing inappropriate molecules that manage to pass the endothelial barrier when it is stressed, thus the loss of pericytes with age implies a decrease in the ability of the BBB to compensate for transient leaks.

A later ultrastructural study of the BBB in AD (Stewart et al., 1992) showed subtle but definite abnormalities suggesting compromise (leakiness) of the BBB in AD. They observed that the percentage of capillary profiles containing at least one pericyte was significantly greater in AD than control brains, as was the number of pericyte profiles/vessel profile. They also showed increased numbers of interendothelial junctions/unit of vessel length and increased numbers of abnormal junctions with junctional gaps.

More recently, research has extended to intracellular signalling pathways common to several neurotransmitter receptors, which might also be targets of the disease process.

Grammas, Roher and Ball (1994) reported that cAMP levels, as an index of adenylyl cyclase activity, are significantly elevated in microvessels from AD patients compared to nondemented elderly controls. According to previous observations (Joo, 1972), increased cAMP is associated with elevated permeability of the BBB. This result suggests, one more time, that abnormal vascular permeability may be a component of AD.

4.5.2) Denervating microangiopathy

A group of evidence supports the idea that a form of denervating microangiopathy may occur in the brains of AD patients causing changes in the permeability of the BBB. More than twenty years ago, Gunn (1971) reported a series of experiments in which the myocardium of experimental animals was completely denervated. Histological study several months later revealed distortion and thickening of the myocardial vessel walls with massive cellular and lipoid infiltration. Assuming that denervation of the vessel walls was significant in the pathogenesis of this effect, some researchers wonder whether or not a similar mechanism might be involved in the genesis of the vascular and parenchymal changes observed in AD. According to this hypothesis, the primary target of the Alzheimer process would be subcortical nuclei which are

thought to supply innervation to cerebral vessels, e.g. locus coeruleus and basal forebrain (Hamel and Estrada, 1989; Kalaria, Stockmeier and Harik, 1989).

It has been reported that destruction of the locus coeruleus in experimental animals results in a significant increase in the density of beta-adrenergic receptors in cerebral microvessels that is suggestive of denervation supersensitivity (Kalaria, Stockmeier and Harik, 1989). The same manipulation produces increased permeability of the BBB to macromolecules, especially under certain pathophysiologic conditions such as seizures and hypertension (Nag and Harik, 1987; Harik and McGunigal, 1984). Destruction of the locus coeruleus also causes a 40% decrease in the activity of the sodium-potassium-ATPase in cerebral microvessels, suggesting a decline in BBB function (Harik, 1986).

In autopsy material Scheibel (1987) observed dramatic changes in the capillary bed of AD patients. These changes included highly irregular cerebral vessels, covered with rounded or conical extrusions; vessel walls that were perforated by multiple openings, which appeared to run through the complete thickness of the basement membrane but did not perforate the endothelial lining; and most important of all, the pericapillary plexus of nerve fibres, which was present on the abluminal surface of cerebral vessels from non-demented subjects, was entirely absent in AD patients.

Harik and Kalaria (1991) studied brain microvessels from AD patients and found a marked decreased of about 50% in the density of the glucose transporter, but increased density of beta2- and alpha2-adrenergic receptors. The authors suggested that the latter observation may be the result of noradrenergic deafferentation of cerebral microvessels, since it is similar to the "denervation supersensitivity" of microvessel beta2-adrenergic receptors that occurs in rats after lesions of the locus coeruleus (Kalaria, Stockmeier and Harik, 1989).

Interesting to mention are the observations of Bondareff et al. (1987) on autopsy material of AD patients. The neuronal density in the locus coeruleus of AD subjects was significantly reduced when compared to controls. The AD group was further divided into two subgroups according to the number of noradrenergic neurons in a section of the locus coeruleus at the site of maximal neuronal density (greater than or less than 65 neurons). Neuronal counts of less than 65 were associated with significantly greater numbers of SP in the temporal cortex, suggesting a relationship between neuronal loss in the locus coeruleus and the development of SP in cortical areas.

According to anatomical and functional evidence, the basal forebrain cholinergic system seems to be involved in the regulation of cortical cerebral blood flow. The basal forebrain constitutes the main source of cholinergic

projection fibres innervating the neocortex (Johnston, McKinney and Coyle, 1979, 1981). Anterograde labeling of basal forebrain neurons revealed a close association between projection fibres and cortical blood vessels (Luiten et al., 1987). In addition, elements within or in close apposition to cortical microvessels synthesize, store and release acetylcholine (Hamel and Estrada, 1989).

Electrical microstimulation of the basal forebrain elicits remarkable increases in cortical cerebral blood flow (up to 280% of control) that are dependent on frequency and current intensity (Raszkiewicz et al., 1992). This response is potentiated by cholinesterase inhibitors such as physostigmine (Dauphin et al., 1991) and is substantially decreased by the nicotinic receptor antagonist mecamylamine (Arneric, 1988). Destruction of basal forebrain neurons results in a topographical loss of cholinergic innervation of the cerebral cortex and a corresponding reduction in resting cerebral blood flow when loss of cholinergic innervation exceeds 40% (Arneric, 1989). It has been also suggested that nitric oxide or a related precursor formed by nitric oxide synthase has a critical role in mediating regulation of cortical cerebral blood flow by basal forebrain neurons (Raszkiewicz et al., 1992).

A series of neuropathological studies have shown significant changes in the basal forebrain cholinergic system

in AD patients. Arendt et al. (1983) reported a mean neuronal loss of 70% in the nucleus basalis of Meynert (part of the basal forebrain) in AD patients compared with age-matched controls, but with large variations between individual cases. On the other hand, Wilcock et al. (1988) found a mean reduction of around 40%, with the most severe loss in the subdivision projecting to the temporal lobe. In a later study Arendt et al. (1984) observed a significant correlation between neuronal loss and mean plaque counts in the cerebral cortex. However, Pearson et al. (1985) found evidence, by using immunocytochemistry for choline acetyltransferase, that some cells in the nucleus were shrunken rather than lost, particularly in older patients.

4.5.3) Cerebral hypoperfusion

Another possible explanation for the pathogenic relationship between severe CVD and SP formation is that hypoperfusion of the brain, in association with severe CVD, may play a role in the genesis of SP (Sparks et al., 1990).

Although cerebral blood flow is decreased in the frontal, parietal and temporal regions in AD patients (Eberling et al., 1992; Frackowiak et al., 1981; Fukuyama et al., 1994; Jobst et al., 1992), some researchers think that this is more likely the result rather than the cause of the disease.

The lower cerebral perfusion is proportionate with the reduced metabolic rate of oxygen and glucose (Frackowiak et al., 1981; Fukuyama et al., 1994), and it is accompanied by an abnormally high metabolic ratio (metabolic rate of oxygen/metabolic rate of glucose) in the temporoparietal region (Fukuyama et al., 1994). This abnormal metabolic ratio suggests that there is an impairment of glucose degradation, which causes a metabolic shift from glycolytic to oxidative metabolism. Furthermore, it has been reported that the oxygen extraction fraction in the brain of AD patients is similar to that of controls (Frackowiak, 1981).

Bell and Ball (1986) studied the microvasculature of the hippocampus and visual cortex (diameters and densities of arterioles and capillaries) as well as the arteries supplying the hippocampus from the posterior cerebral artery. These authors found that none of the three cerebral vascular systems studied revealed a significant difference in carrying capacity between normal old and AD cases, which were equally reduced compared to the normal young state. They concluded that it seemed unlikely that Alzheimer lesions resulted from inadequate irrigation of the brain.

However, as they also pointed out, it cannot be assumed that a greater potential vascular capacity automatically results in a greater blood flow. It is mandatory to consider as well the physiological mechanisms involved in the control

of vascular contraction and relaxation.

A key role in these mechanisms is played by nitric oxide (NO). The vascular involvement of NO has been elucidated over the past fourteen years since the original work of Furchgott and Zawadzki (1980). It has been shown that NO released by vascular endothelial cells is a powerful vasodilator. The factors involved in the control of NO synthesis and release have not been fully worked out, although L-arginine has been demonstrated to be the substrate for NO production, and various vasoactive agents such as acetylcholine and bradykinin have been shown to stimulate its synthesis and release (Moncada, Palmer and Higgs, 1991).

It has been demonstrated that perivascular innervation is involved in the acetylcholine-induced endothelium-dependent relaxation of the superior mesenteric arterial bed in the rat (Miller and Scott, 1990; Scott and Chafe, 1994a; Scott, Drodge and Foote, 1992). It is not known, however, if this is a universal phenomenon present in all arterial beds or whether it is limited to particular parts of the arterial network.

Among the different neuropeptides present in the perivascular nervous plexus, calcitonin gene-related peptide (CGRP) seems to play an important modulatory role in endothelium-dependent vascular relaxation. CGRP replacement in denervated vessels improves the ability of acetylcholine to induce relaxation, while treatment of innervated preparations

with the inhibitor CGRP8-37 results in a reduction in acetylcholine-induced relaxation (Scott and Chafe, 1994b).

A depression of the NO system has been reported to occur in various situations, some of which are also associated with changes in perivascular innervation. Depression of NO-induced relaxation occurs in both aorta and small vessels of genetically hypertensive rats (De Mey and Gray, 1985; Konishi and Su, 1983; Winquist et al., 1984), aortic coarcted rats (Lockette, Otsuka and Carretero, 1986), mineralocorticoid-induced hypertensive rats (Mayhan, Faraci and Heistad, 1987), hypertensive Dahl rats (Luscher, Raij and Vanhoutte, 1987), and in aortic coarctation hypertensive rabbits (Miller, Pinto and Mullane, 1987).

Furthermore, in hypertension changes occur in the type and pattern of perivascular innervation. It has been demonstrated that during the development of hypertension in the spontaneously hypertensive rat there is an increased density of catecholaminergic fibres in certain vascular beds (Dhital et al., 1988; Donohue et al., 1986; Scott and Pang, 1983). Some changes have been also reported in peptidergic innervation of blood vessels in hypertension, although these are not universal (Lee et al., 1988; Scott, Robinson and Foote, 1986).

The neuronal involvement of NO has only recently been elucidated. Evidence suggests that NO mediates N-methyl-D-

aspartate (NMDA) receptor-linked excitotoxicity (Bredt and Snyder, 1992; Garthwaite, 1991), which seems to play a key role in hippocampal damage following cerebral ischemia and perhaps also in AD (Greenamyre and Young, 1989).

Recent evidence that NO may function as a rapidly produced diffusible messenger within the brain, has led to proposals that it may be involved in the neural mechanism of memory (Gally et al., 1990). Holscher and Rose (1992) have shown that injection of the NO synthase inhibitor N-nitro-L-arginine prior to training in chicks results in amnesia for passive avoidance tasks; the amnesia can be overcome by injecting L-arginine together with the inhibitor, verifying that NO plays a role in memory function.

In our study we analyzed quantitatively the presence of SP in the superior and inferior watershed areas, which correspond with the border zones between the territories supplied by the anterior and middle cerebral arteries and the middle and posterior cerebral arteries, respectively. It is known that occlusion of large arteries in the neck or decreased cardiac output and/or systemic hypotension, in the absence of occlusion of these arteries, can cause selective infarction in these arterial border zones (Romanul and Abramowicz, 1964).

We observed increased numbers of SP in the inferior watershed area of CVD subjects as compared to controls, but

not in the superior watershed area. The latter result does not rule out hypoperfusion as a contributing factor in the development of SP, since many specimens of the superior watershed area, collected at the level of the lateral geniculate nuclei, contained portions of the primary motor cortex, which is well known to be scarcely affected even in AD patients (Arnold et al. 1991; Esiri, Pearson and Powell, 1986; Pearson et al., 1985).

The inferior watershed area, on the other hand, was heavily affected in seven of the 11 CVD patients in whom the area was studied, two other cases showed mild accumulation of SP, and only two subjects were completely free of plaques. However, these results do not constitute a strong enough support for the involvement of hypoperfusion in the genesis of SP. The inferior watershed area is located in the temporal lobe, which is the most affected area of the brain in AD (Tomlinson, 1982, 1992) and CVD patients. As a result of that, we speculate that if hypoperfusion plays a role in the development of SP, it must be a localized rather than a generalized hypoperfusion, which may be dependent on the conditions of the local microenvironment.

It is not clear, of course, what these local factors might be, but a possible candidate could be the existence of a particularly severe denervating microangiopathy in those areas more heavily affected by SP. The association between

lower neuronal counts in the locus coeruleus and greater numbers of SP in the temporal cortex (Bondareff et al., 1987), and the observation that the most severe neuronal loss in the nucleus basalis of Meynert occurs in the subdivision projecting to the temporal lobe (Wilcock et al., 1988) support this idea.

4.6) Summary and Conclusions

The present study has demonstrated that non-demented patients with severe CVD have a higher prevalence of SP than non-demented, non-heart disease control subjects. CVD patients also showed significantly higher SP counts in the inferior watershed area, dentate gyrus, subiculum and transentorhinal cortex when compared to the control group. These two groups; however, were not different when the prevalence and mean counts of NFT were considered.

The distribution of SP was similar in CVD and AD patients. The fact that the main differences between them were the amount and type of plaques, places the CVD group in an intermediate position in the spectrum of SP formation between the AD patients and the controls. According to this, if we consider AD patients as having the fully developed pathological picture, CVD subjects could be considered as an

earlier stage characterized by a lower density of SP, most of them being of the diffuse type, and a more limited involvement of cortical layers in the affected areas.

Our results further suggest that SP in AD and CVD patients may have a common origin, with a cardiovascular component in their pathogenetic mechanism. A BBB impairment, the existence of a denervating microangiopathy and cerebral hypoperfusion have been discussed as probably related factors. This work also indicates that the study of patients with severe CVD might help to clarify the natural history of SP, and raises the question of whether or not these patients should be used as non-demented controls in AD research.

Finally, we have also observed that the cerebellum and the caudate nucleus are more frequently affected in AD than previously thought, although the clinical implications of the lesions encountered are not clear yet.

REFERENCES

- Aharon-Peretz J, Cummings JL, Hill MA (1988) Vascular dementia and dementia of the Alzheimer type. Cognition, ventricular size and leukoaraiosis. *Arch Neurol*, 45: 719-721.
- Akiyama H, Yamada T, McGeer PL, Kawamata T, Tooyama I, Ishii T (1993) Columnar arrangement of beta-amyloid protein deposits in the cerebral cortex of patients with Alzheimer's disease. *Acta Neuropathol*, 85: 400-403.
- American Academy of Neurology (1980) Annual Course no. 9: Neuropathology (McCormick WF, chairman). New Orleans, Louisiana, pp. 75-92.
- American Psychiatric Association (1987) Diagnostic and Statistical Manual of Mental Disorders (DSM III-R). 3rd. edition (revised). Washington, DC, pp. 103-123.
- Arai H, Sugai N, Noguchi I, Haga S, Ishii T, Makino Y, Kosaka K (1989) An immunohistochemical study of beta-protein in Alzheimer-type dementia brains. *J Neurol*, 236: 214-217.
- Arendt T, Bigl V, Arendt A, Tennstedt A (1983) Loss of neurons in the nucleus basalis of Meynert in Alzheimer's disease, paralysis agitans and Korsakoff's disease. *Acta Neuropathol*, 61: 101-108.
- Arendt T, Bigl V, Tennstedt A, Arendt A (1984) Correlations between cortical plaque count and neuronal loss in the nucleus basalis in Alzheimer's disease. *Neurosci Lett*, 48: 81-85.
- Arneric SP (1988) Cortical cerebral blood flow (CBF) is increased by electrical stimulation of the basal forebrain (BF): Modulation by cholinergic mechanisms. *Soc Neurosci Abstr*, 14: 488.2.
- Arneric SP (1989) Cortical cerebral blood flow is modulated by cholinergic basal forebrain neurons: Effects of ibotenic acid lesions and electrical stimulation. In Seylaz J, MacKenzie ET (eds): *Excerpta Medica International Congress Series*. vol. 869. New York, Elsevier, pp. 381-384.
- Arnold SE, Hyman BT, Flory J, Damasio AR, Van Hoesen GW (1991) The topographical and neuroanatomical distribution of neurofibrillary tangles and neuritic plaques in the

cerebral cortex of patients with Alzheimer's disease. Cereb Cortex, 1: 103-116.

Aronson MK, Ooi WL, Morgenstern H, Hafner A, Masor D, Crystal H, Frishman WH, Fisher D, Katzman R (1990) Women, myocardial infarction, and dementia in the very old. Neurology, 40: 1102-1106.

Arriagada PV, Growdon JH, Hedley-Whyte ET, Hyman BT (1992) Neurofibrillary tangles but not senile plaques parallel duration and severity of Alzheimer's disease. Neurology, 42: 631-639.

Arriagada PV, Marzloff K, Hyman BT (1992) Distribution of Alzheimer-type pathologic changes in nondemented elderly individuals matches the pattern in Alzheimer's disease. Neurology, 42: 1681-1688.

Ball MJ (1977) Neuronal loss, neurofibrillary tangles and granulovacuolar degeneration in the hippocampus with aging and dementia - A quantitative study. Acta Neuropathol, 37: 111-118.

Ball MJ (1978) Topographic distribution of neurofibrillary tangles and granulovacuolar degeneration in hippocampal cortex of aging and demented patients: A quantitative study. Acta Neuropathol, 42: 73-80.

Ball MJ (1988) Hippocampal histopathology-a critical substrate for dementia of the Alzheimer type. In Ulrich J (ed): Interdisciplinary Topics on Gerontology. vol. 25: Histology and Histopathology of the Aging Brain. Karger, Basel, pp. 16-37.

Ball M, Hachinski V, Fox A, Kirshen A, Fisman M, Blume W, Kral V, Fox H, Merskey H (1985) A new definition of Alzheimer's disease: A hippocampal dementia. Lancet I: 14-16.

Bancher C, Braak H, Fischer P, Jellinger KA (1993) Neuropathological staging of Alzheimer lesions and intellectual status in Alzheimer's and Parkinson's disease patients. Neurosci Lett, 162: 179-182.

Bancher C, Brunner C, Lassmann H, Budka H, Jellinger KA, Seitelberger F, Grundke-Iqbal I, Iqbal K, Wisniewski HM (1989) Tau and ubiquitin immunoreactivity at different stages of formation of Alzheimer neurofibrillary tangles. Prog Clin Biol Res, 317: 837-848.

- Barr ML, Kiernan JA (1993) The Human Nervous System. An Anatomical Viewpoint. 6th. ed. JB Lipincott Co, Philadelphia, pp. 278-290.
- Battersby C, Hartley K, Fletcher AE, Markowe HJL, Brown RG, Styles W, Carne S, Jamieson T, Koppel I, Fraser S, Sapper H, Bulpitt CJ (1993) Cognitive function in hypertension: A community based study. *J Hum Hypertens*, 7: 117-123.
- Beach TG, McGeer EG (1992) Senile plaques, amyloid beta-protein, and acetylcholinesterase fibres: Laminar distribution in Alzheimer's disease striate cortex. *Acta Neuropathol*, 83: 292-299.
- Beats B, Levy R, Forstl H (1991) Ventricular enlargement and caudate hyperdensity in elderly depressives. *Biol Psychiatry*, 30: 452-458.
- Bell MA, Ball MJ (1985) Laminar variation in the microvascular architecture of normal human visual cortex (area 17). *Brain Res*, 335: 139-143.
- Bell MA, Ball MJ (1986) The correlation of vascular capacity with the parenchymal lesions of Alzheimer's disease. *Can J Neurol Sci*, 13: 456-461.
- Bendel P, Eilman R (1992) Quantitation of ventricular size in normal and spontaneously hypertensive rats by magnetic resonance imaging. *Brain Res*, 574: 224-228.
- Berg L, McKeel DW, Miller JP, Baty J, Morris JC (1993) Neuropathological indexes of Alzheimer's disease in demented and nondemented persons aged 80 years and older. *Arch Neurol*, 50: 349-358.
- Bergeron C, Ranalli RJ, Miceli PN (1987) Amyloid angiopathy in Alzheimer's disease. *Can J Neurol Sci*, 14: 564-569.
- Blatted S (1956) Hippocampal projections and related neural pathways. *Brain*, 81: 319-340.
- Blessed G, Tomlinson BE, Roth M (1968) The association between quaitative measures of dementia and of senile change in the cerebral grey matter of elderly subjects. *Br J Psychiatry*, 114: 797-811.
- Blinkov SM, Glezer II (1968) The human brain in figures and tables. Basic Books Inc, Plenum Press, New York, pp. 2-4.

- Boller F, Vrtunski B, Mack J, Kim Y (1977) Neuropsychological correlates of hypertension. *Arch Neurol*, 34: 701-705.
- Bondareff W, Mountjoy CQ, Roth M, Rossor MN, Iversen LL, Reynolds GP (1987) Age and histopathologic heterogeneity in Alzheimer's disease. Evidence for subtypes. *Arch Gen Psychiatry*, 44: 412-417.
- Braak H, Braak E (1985) On areas of transition between entorhinal allocortex and temporal isocortex in the human brain. Normal morphology and lamina-specific pathology in Alzheimer's disease. *Acta Neuropathol*, 68: 325-332.
- Braak H, Braak E (1988) Neuropil threads occur in dendrites of tangle-bearing nerve cells. *Neuropath Appl Neurobiol*, 14: 39-44.
- Braak H, Braak E (1990a) Neurofibrillary changes confined to the entorhinal region and an abundance of cortical amyloid in cases of presenile and senile dementia. *Acta Neuropathol*, 80: 479-486.
- Braak H, Braak E (1990b) Alzheimer's disease: Striatal amyloid deposits and neurofibrillary changes. *J Neuropathol Exp Neurol*, 49: 215-224.
- Braak H, Braak E, Bohl J (1993) Staging of Alzheimer-related cortical destruction. *Eur Neurol*, 33: 403-408.
- Braak H, Braak E, Bohl J, Lang W (1989) Alzheimer's disease: Amyloid plaques in the cerebellum. *J Neurol Sci*, 93: 277-287.
- Braak H, Braak E, Kalus P (1989) Alzheimer's disease: Areal and laminar pathology in the occipital isocortex. *Acta Neuropathol*, 77: 494-506.
- Bredt DS, Snyder SH (1992) Nitric oxide, a novel neuronal messenger. *Neuron*, 8: 3-11.
- Breitner JCS, Murphy EA, Silverman JM, Mohs RC, Davis KL (1988) Age-dependent expression of familial risk in Alzheimer's disease. *Am J Epidemiol*, 128: 536-548.
- Brillman J (1993) Central nervous system complications in coronary artery bypass graft surgery. *Neurol Clin*, 11: 475-495.

- Brucher JM, Gillain C, Baron H (1989) Cerebellar amyloid plaques in Alzheimer's disease. *Acta Neurol Belg*, 89: 286-293.
- Brun A, Englund E (1981) Regional pattern of degeneration in Alzheimer's disease: Neuronal loss and histopathological grading. *Histopathology*, 5: 549-564.
- Brun A, Englund E (1986) A white matter disorder in dementia of Alzheimer type: A pathoanatomical study. *Ann Neurol*, 19: 253-262.
- Bugiani O, Giaccone G, Frangione B, Ghetti B, Tagliavini F (1989) Alzheimer patients: Preamyloid deposits are more widely distributed than senile plaques throughout the central nervous system. *Neurosci Lett*, 103: 263-268.
- Burns A, Philpot MP, Costa DC, Ell PJ, Levy R (1989) The investigation of Alzheimer's disease with single photon emission tomography. *J Neurol Neurosurg Psychiatry*, 52: 248-253.
- Burt AM (1993) *Textbook of Neuroanatomy*. WB Saunders, Philadelphia, pp. 335-347.
- Cancilla PA, Baker RN, Pollock PS, Frommes SP (1972) The reaction of pericytes of the central nervous system to exogenous proteins. *Lab Invest*, 26: 376-383.
- Carpenter MK, Crutcher KA, Kater SB (1993) An analysis of the effects of Alzheimer's plaques on living neurons. *Neurobiol Aging*, 14: 207-215.
- Casanova MF, Carosella NW, Gold JM, Kleinman JE, Weinberger DR, Powers RE (1993) A topographical study of senile plaques and neurofibrillary tangles in the hippocampi of patients with Alzheimer's disease and cognitively impaired patients with schizophrenia. *Psychiatry Res*, 49: 41-62.
- Cerebral Embolism Task Force (1986) Cardiogenic brain embolism. *Arch Neurol*, 43: 71.
- Coffey EE, Massey EW, Roberts KB, Curtis S, Jones RH, Pryor DB (1983) Natural history of cerebral complications of coronary artery bypass graft surgery. *Neurology*, 33: 1416-1421.

- Cole G, Neal JW, Singhrao SK, Jasani B, Newman GR (1993) The distribution of amyloid plaques in the cerebellum and brain stem in Down's syndrome and Alzheimer's disease: A light microscopical analysis. *Acta Neuropathol*, 85: 542-552.
- Cole G, Williams P, Alldryck D, Singhrao SK (1989) Amyloid plaques in the cerebellum in Alzheimer's disease. *Clin Neuropathol*, 8: 188-191.
- Coria F, Moreno A, Rubio I, Garcia MA, Morato E, Mayor F Jr (1993) The cellular pathology associated with Alzheimer beta-amyloid deposits in non-demented aged individuals. *Neuropathol Appl Neurobiol*, 19: 261-268.
- Cork LC, Sternberger NH, Sternberger LA, Casanova MF, Struble RG, Price DL (1986) Phosphorylated neurofilament antigens in neurofibrillary tangles in Alzheimer's disease. *J Neuropathol Exp Neurol*, 45: 56-64.
- Corseillis JAN (1976) Some observations on the Purkinje cell population and on brain volume in human aging. In Terry RD, Gershon S (eds): *Neurobiology of Aging*. vol. 3. Raven Press, New York, p. 205.
- Crystal H, Dickson D, Fuld P, Masur D, Scott R, Mehler M, Masdeu J, Kawas C, Aronson M, Wolfson L (1988) Clinico-pathologic studies in dementia: Nondemented subjects with pathologically confirmed Alzheimer's disease. *Neurology*, 38: 1682-1687.
- Culling CFA (1974) *Handbook of Histopathological and Histochemical Techniques*. 3rd. ed. Butterworths, London, pp. 446-447.
- Dauphin F, Lacombe P, Sercombe R, Hamel E, Seylaz J (1991) Hypercapnia and stimulation of the substantia innominata increase rat frontal cortical blood flow by different cholinergic mechanisms. *Brain Res*, 553: 75-83.
- Delacourte A, Defossez A, Persuy P, Peers MC (1987) Observation of morphological relationships between angiopathic blood vessels and degenerative neurites in Alzheimer's disease. *Virchows Arch (A)*, 411: 199-204.
- Delaere P, He Y, Fayet G, Duyckaerts C, Hauw JJ (1993) BetaA4 deposits are constant in the brain of the oldest old: An immunocytochemical study of 20 French centenarians. *Neurobiol Aging*, 14: 191-194.

- de la Monte SM (1989) Quantitation of cerebral atrophy in preclinical and end-stage Alzheimer's disease. *Ann Neurol*, 25: 450-459.
- De Mey JG, Gray SD (1985) Endothelium-dependent reactivity in resistant vessels. *Prog Appl Microcirc*, 8: 181-187.
- Dhital KK, Gerli R, Lincoln J, Milner P, Tanganelli P, Weber G, Fruschelli C, Burnstock G (1988) Increased density of perivascular nerves to the major cerebral vessels of the spontaneously hypertensive rat: Differential changes in noradrenaline and neuropeptide Y during development. *Brain Res*, 444: 33-45.
- Dickson DW, Farlo J, Davies P, Crystal H, Fuld P, Yen SH (1988) Alzheimer's disease: A double labeling immunohistochemical study of senile plaques. *Am J Pathol*, 132: 86-101.
- Dickson DW, Ksiezak-Reding H, Davies P, Yen SH (1987) A monoclonal antibody that recognizes a phosphorylated epitope in Alzheimer neurofibrillary tangles, neurofilaments and tau proteins immunostains granulovacuolar degeneration. *Acta Neuropathol*, 73: 254-258.
- Donohue M, Stutzel R, Robinson R, Head RJ (1986) Hypernoradrenergic innervation in the spontaneously hypertensive rat (SHR) occurs before the onset of hypertension. *Fed Proc*, 45: 194.
- Duchen LW, Jacobs JM (1989) Nutritional deficiencies and metabolic disorders. In Adams JH, Corsellis JAN, Duchen LW (eds): *Greenfield's Neuropathology*. 4th. ed. John Wiley and Sons Inc, New York, p. 612.
- Duyckaerts C, Hauw JJ, Bastenaire F, Piette F, Poulain V, Rainsard C, Javoid-Agid F, Berthaux P (1986) Laminar distribution of neocortical senile plaques in senile dementia of the Alzheimer type. *Acta Neuropathol*, 70: 249-256.
- Duyckaerts C, Hauw JJ, Piette F, Rainsard C, Poulain V, Berthaux P, Escourolle R (1985) Cortical atrophy in senile dementia of the Alzheimer type is mainly due to a decrease in cortical length. *Acta Neuropathol*, 66: 72-74.

- Duyckaerts C, Kawasaki H, Delaere P, Rainsard C, Hauw JJ (1989) Fibre disorganization in the neocortex of patients with senile dementia of the Alzheimer type. *Neuropathol Appl Neurobiol*, 15: 233-247.
- Eberling JL, Jagust WJ, Reed BR, Baker MG (1992) Reduced temporal lobe blood flow in Alzheimer's disease. *Neurobiol Aging*, 13: 483-491.
- Emre M, Geula C, Ransil BJ, Mesulam MM (1992) The acute neurotoxicity and effects upon cholinergic axons of intracerebrally injected beta-amyloid in the rat brain. *Neurobiol Aging*, 13: 553-559.
- Esiri MM, Pearson RCA, Powell TPS (1986) The cortex of the primary auditory area in Alzheimer's disease. *Brain Res*, 366: 385-387.
- Evans DA, Funkenstein HH, Albert MS, Scherr PA, Cook NR, Chown MJ, Hebert LE, Hennekens CH, Taylor JO (1989) Prevalence of Alzheimer's disease in a community population of older persons: Higher than previously reported. *JAMA*, 262: 2551-2556.
- Foulkes MA, Wolf PA, Price TR, Mohr JP, Hier DB (1988) The Stroke Data Bank: Design, methods, and baseline characteristics. *Stroke*, 19: 547.
- Frackowiak RSJ, Pozzelli C, Legg NJ, DuBoulay GH, Marshall J, Lenzi GL, Jones T (1981) Regional cerebral oxygen supply and utilization in dementia: A clinical and physiological study with oxygen-15 and positron tomography. *Brain*, 104: 753-778.
- Franceschi M, Tancredi O, Smirne S, Mercinelli A, Canal N (1982) Cognitive process in hypertension. *Hypertension*, 4: 226-229.
- Friedland RP, Jagust WJ, Budinger TF, Koss E, Ober BA (1987) Consistency of temporal-parietal cortex hypometabolism in probable Alzheimer's disease (AD): Relationship to cognitive decline. *Neurology*, 37 (suppl. 1): 224.
- Furchtgott RF, Zawadski JV (1980) The obligatory role of endothelial cells in the relaxation of smooth muscle by acetylcholine. *Nature*, 288: 373-376.

- Fukuyama H, Ogawa M, Yamaguchi H, Yamaguchi S, Kimura J, Yonekura Y, Konishi J (1994) Altered cerebral energy metabolism in Alzheimer's disease: A PET study. *J Nucl Med*, 35: 1-6.
- Galloway PG, Perry G, Gambetti P (1987) Hirano body filaments contain actin and actin associated proteins. *J Neuropathol Exp Neurol*, 46: 185-199.
- Gally JA, Montague RP, Reeke GN, Edelman GM (1990) The NO hypothesis: Possible effects of a short-lived rapidly diffusible signal in the development and function of the nervous system. *Proc Natl Acad Sci USA*, 87: 3547-3551.
- Games D, Khan KM, Soriano FG, Keim PS, Davis DL, Bryant K, Lieberburg I (1992) Lack of Alzheimer pathology after beta-amyloid protein injections in rat brain. *Neurobiol Aging*, 13: 569-576.
- Gandy S, Greengard P (1992) Amyloidogenesis in Alzheimer's disease: Some possible therapeutic opportunities. *Trends Pharmacol Sci*, 13: 108-113.
- Garthwaite J (1991) Glutamate, nitric oxide and cell-cell signaling in the nervous system. *Trends Neurosci*, 14: 60-67.
- Garvey W, Fathi A, Bigelow F, Jimenez CL, Carpenter BF (1991) Rapid, reliable and economical silver stain for neurofibrillary tangles and senile plaques. *J Histotechnol*, 14: 39-42.
- Geddes JW, Lundgren K, Kim YK (1991) Aberrant localization of MAP5 immunoreactivity in the hippocampal formation in Alzheimer's disease. *J Neurosci Res*, 30: 183-191.
- Giannakopoulos P, Hof PR, Surini M, Michel JP, Bouras C (1993) Quantitative immunohistochemical analysis of the distribution of neurofibrillary tangles and senile plaques in the cerebral cortex of nonagenarians and centenarians. *Acta Neuropathol*, 85: 602-610.
- Gibson PH, Stones M, Tomlinson BE (1976) Senile changes in the human neocortex and hippocampus compared by the use of electron and light microscopes. *J Neurol Sci*, 27: 389-405.

- Goldgaber D, Lerman MI, McBride OW, Saffiotti U, Gajdusek DC (1987) Characterization and chromosomal localization of a cDNA encoding brain amyloid of Alzheimer's disease. *Science*, 235: 877-880.
- Goldman H, Kleinman K, Snow M, Bidus D, Korol B (1974) Correlation of diastolic blood pressure and signs of cognitive dysfunction in essential hypertension. *Dis Nerv Sys*, 35: 571-572.
- Goodman L (1953) Alzheimer's disease, a clinico-pathologic analysis of twenty-three cases with a theory on pathogenesis. *J Nerv Ment Dis*, 118: 97-130.
- Grammas P, Roher AE, Ball MJ (1994) Increased accumulation of cAMP in cerebral microvessels in Alzheimer's disease. *Neurobiol Aging*, 15: 113-116.
- Greenamyre JT, Young AB (1989) Excitatory amino acids and Alzheimer's disease. *Neurobiol Aging*, 10: 593-602.
- Grundka-Iqbal I, Iqbal K, Quinlan M, Tung YC, Zaidi MS, Wisniewski HM (1986) Microtubule-associated protein tau. A component of Alzheimer paired helical filaments. *J Biol Chem*, 261: 6084-6089.
- Gunn CG (1971) Proliferative nature of arteriosclerosis and regulators of metabolism and movement. In Wolfe S (ed): *The Artery and the Process of Arteriosclerosis*. Plenum Press, New York, pp. 56, 230.
- Gutzmann H, Kuhl KP (1987) Emotion control and cerebellar atrophy in senile dementia. *Arch Gerontol Geriatr*, 6: 61-71.
- Halliday G, Flowers D, Baum L (1994) Analysis of staining methods for different cortical plaques in Alzheimer's disease. *Acta Neuropathol*, 87: 174-186.
- Hamel E, Estrada C (1989) Cholinergic innervation of pial and intracerebral blood vessels: Evidence, possible origins and sites of action. In Seylaz J, Sercombe R (eds): *Neurotransmission and Cerebrovascular Function*. vol. II. Elsevier, New York, pp. 151-173.
- Harik SI (1986) Blood-brain barrier sodium/potassium pump: Modulation by central noradrenergic innervation. *Proc Natl Acad Sci USA*, 83: 4067-4070.

- Harik SI, Kalaria RN (1991) Blood-brain barrier abnormalities in Alzheimer's disease. *Ann NY Acad Sci*, 640: 47-52.
- Harik SI, McGunigal T Jr (1984) The protective influence of the locus ceruleus on the blood-brain barrier. *Ann Neurol*, 15: 568-574.
- Helgason CM, Sherman DG (1989) Neurologic manifestations of cardiac disease. *Neurol Clin*, 7: 469-488.
- Heller S, Kornfeld D (1986) Psychiatric aspects of cardiac surgery. *Adv Psychosom Med*, 15: 124-139.
- Henderson AS (1990) Epidemiology of dementing disorders. In Wurtman RJ, Browdon JH, Corkin S (eds): *Alzheimer's Disease*. Raven Press, New York, pp. 15-25.
- Henderson AS, Kay DWK (1984) The epidemiology of mental disorders in the aged. In Kay DWK, Burrows GD (eds): *Handbook of Studies on Psychiatry and Old Age*. Elsevier, New York, pp. 53-88.
- Hirano A, Zimmerman HM (1962) Alzheimer's neurofibrillary changes: A topographic study. *Arch Neurol*, 7: 227-242.
- Ho KC, Roessmann U, Straumfjord JV, Monroe G (1980) Analysis of brain weight. I. Adult brain weight in relation to sex, race and age. *Arch Pathol Lab Med*, 104: 635-639.
- Holscher C, Rose SPR (1992) An inhibitor of nitric oxide synthesis prevents memory formation in the chick. *Neurosci Lett*, 145: 165-167.
- Hooper M, Vogel F (1976) The limbic system in Alzheimer's disease. *Am J Pathol*, 85: 1-19.
- Horvath TB, Siever LJ, Mohs RC, Davis K (1989) Organic mental syndromes and disorders. In Kaplan HI, Sadock BJ (eds): *Comprehensive Textbook of Psychiatry*. 5th. ed. vol. 1. Williams and Wilkins, Baltimore, pp. 599-641.
- Hubbard BM, Anderson JM (1981) A quantitative study of cerebral atrophy in old age and senile dementia. *J Neurol Sci*, 50: 135-145.
- Hyman BT, Van Hoesen GW, Damasio A, Barnes C (1984) Alzheimer's disease: Cell-specific pathology isolates the hippocampal formation. *Science*, 225: 1168-1170.

- Hyman BT, Van Hoesen GW, Kromer L, Damasio A (1986) Perforant pathway changes and the memory impairment of Alzheimer's disease. *Ann Neurol*, 20: 472-481.
- Ihara Y (1988) Massive somatodendritic sprouting of cortical neurons in Alzheimer's disease. *Brain Res*, 459: 138-144.
- Ikeda K, Haga C, Oyanagi S, Iritani S, Kosaka K (1992) Ultrastructural and immunohistochemical study of degenerative neurite-bearing ghost tangles. *J Neurol*, 239: 191-194.
- Ishii T (1958) Histochemistry of the senile changes of the brain of the senile dementia. *Psychiatr Neurol Jpn*, 60: 768-781.
- Jacobs JM, Le Quesne PM (1984) Toxic disorders of the nervous system. In Adams JH, Corsellis JAN, Duchen LW (eds): *Greenfield's Neuropathology*. 4th. ed. John Wiley and Sons Inc, New York, pp. 637-641.
- Jamada M, Mehraein P (1968) Verteilungsmuster der senilen veränderungen im gehirn beteiligung des limbischen systems bei hirnatrophischen prozessen des seniums und bei morbus Alzheimer. *Arch Psychiatr Neurol*, 211: 308-324.
- Jellinger K (1976) Neuropathological aspects of dementias resulting from abnormal blood and cerebrospinal fluid dynamics. *Acta Neurol Belg*, 76: 83-102.
- Joachim CL, Morris JH, Selkoe DJ (1989) Diffuse amyloid plaques occur commonly in the cerebellum in Alzheimer's disease. *Am J Pathol*, 135: 309-319.
- Jobst KA, Smith AD, Barker CS, Wear A, King EM, Smith A, Anslow PA, Molyneux AJ, Shepstone BJ, Soper N, Holmes KA, Robinson JR, Hope RA, Oppenheimer C, Brockbank K, McDonald B (1992) Association of atrophy of the medial temporal lobe with reduced blood flow in the posterior parietotemporal cortex in patients with a clinical and pathological diagnosis of Alzheimer's disease. *J Neurol Neurosurg Psychiatry*, 55: 190-194.
- Johnston MV, McKinney M, Coyle JT (1979) Evidence for a cholinergic projection to neocortex from neurons in basal forebrain. *Proc Natl Acad Sci USA*, 76: 5392-5396.

- Johnston MV, McKinney M, Coyle JT (1981) Neocortical cholinergic innervation: A description of extrinsic and intrinsic components. *Exp Brain Res*, 43: 159-172.
- Joo F (1972) Effect of N602-dibutylryl cyclic 3'5'-adenosine monophosphate on the pinocytosis of brain capillaries of mice. *Experientia*, 28: 1470-1471.
- Kachaturian SZ (1985) Diagnosis of Alzheimer's disease. *Arch Neurol*, 42: 1097-1105.
- Kalaria RN, Stockmeier CA, Harik SI (1989) Brain microvessels are innervated by locus ceruleus noradrenergic neurons. *Neurosci Lett*, 97: 203-208.
- Kang J, Lemaire HG, Unterbeck A, Salbaum JM, Masters CL, Grzeschik KH, Multhaup G, Beyreuther K, Muller-Hill B (1987) The precursor of Alzheimer's disease amyloid A4 protein resembles a cell surface receptor. *Nature*, 325: 733-736.
- Katzman R (1986) Alzheimer's disease. *N Engl J Med*, 314: 964-973.
- Katzman R (1989) The dementias. In Rowland P (ed): *Merritt's Textbook of Neurology*. 8th. ed. Lea and Febiger, Philadelphia, pp. 637-644.
- Katzman R, Terry R, DeTeresa R, Brown T, Davies P, Fuld P, Renbing X, Peck A (1988) Clinical, pathological and neurochemical changes in dementia: A subgroup with preserved mental status and numerous neocortical plaques. *Ann Neurol*, 23: 138-144.
- Kawai M, Kalaria RN, Harik SI, Perry G (1990) The relationship of amyloid plaques to cerebral capillaries in Alzheimer's disease. *Am J Pathol*, 137: 1435-1446.
- Kemper TL (1978) Senile dementia: A focal disease of the temporal lobe. In Nandy K (ed): *Senile Dementia: A Biochemical Approach*. Elsevier/North Holland, Amsterdam, pp. 105-113.
- Kitamoto T, Ogomori K, Tateishi J, Prusiner SB (1987) Formic acid pretreatment enhances immunostaining of cerebral and systemic amyloids. *Lab Invest*, 57: 230-236.

- Konoshi M, Su C (1983) Role of endothelium in dilator responses of spontaneously hypertensive rat arteries. *Hypertension*, 5: 881-886.
- Koo EH, Price DL (1993) The neurobiology of dementia. In Whitehouse PJ (ed): *Contemporary Neurology Series*. vol. 40: Dementia. FA Davis, Philadelphia, pp. 55-91.
- Korenschevsky V (1961) *Physiological and Pathological Aging*. Bourne GH (ed), Karger, Basel and New York.
- Kosik KS, Duffy LK, Dowling MM, Abraham C, McCluskey A, Selkoe DJ (1984) Microtubule-associated protein 2: Monoclonal antibodies demonstrate the selective incorporation of certain epitopes into Alzheimer neurofibrillary tangles. *Proc Natl Acad Sci USA*, 81: 7941-7945.
- Kosik KS, Joachim CL, Selkoe DJ (1986) Microtubule-associated protein (tau) is a major antigenic component of paired helical filaments in Alzheimer's disease. *Proc Natl Acad Sci USA*, 83: 4044-4048.
- Kowall NW, McKee AC, Yankner BA, Beal MF (1992) In vivo neurotoxicity of beta-amyloid [B(1-40)] and the B(25-35) fragment. *Neurobiol Aging*, 13: 537-542.
- Krishnan KR, McDonald WM, Escalone PR, Doraiswamy PM, Na C, Housain MM, Figiel GS, Boyko OB, Ellinwood GH, Nemeroff CB (1992) Magnetic resonance imaging of the caudate nucleus in depression. *Arch Gen Psychiatry*, 49: 553-557.
- Kurosawa H, Shimizu Y, Nishimatsu Y, Hirose S, Takano T (1983) The relationship between mental disorders and physical severities in patients with acute myocardial infarction. *Jpn Circ J*, 47: 723-728.
- Lasser NL, Nash J, Lasser VI, Hamill SJ, Batey DM (1989) Effects of antihypertensive therapy on blood pressure control, cognition and reactivity. *Am J Med*, 86 (suppl. 1B): 98-103.
- Lee RM, Nagahama M, McKenzie R, Daniel EE (1988) Peptide-containing nerves around blood vessels of stroke-prone spontaneously hypertensive rats. *Hypertension*, 11: 1117-1120.
- Lee VMY, Balin BJ, Otvos L, Trojanowski JQ (1991) A68: A major subunit of paired helical filaments and derivatized forms of normal tau. *Science*, 251: 675-678.

- Lehr RP, Browning RA, Myers JH (1980) Gross morphological differences between Wistar-Kyoto and spontaneously hypertensive rats. *Clin Exp Hypertens*, 2: 123-127.
- Li YT, Woodruff-Pak DS, Trojanowski JQ (1994) Amyloid plaques in cerebellar cortex and the integrity of Purkinje cell dendrites. *Neurobiol Aging*, 15: 1-9.
- Lichter I, Richardson PJ, Wyke MA (1986) Differential effects of atenolol and enalapril on memory during treatment for essential hypertension. *Br J Clin Pharmacol*, 21: 641-645.
- Lockette W, Otsuka Y, Carretero O (1986) The loss of endothelium-dependent vascular relaxation in hypertension. *Hypertension*, 8: II61-II66.
- Luiten PGM, Gaykema RPA, Traber J, Spencer DG (1987) Cortical projection patterns of magnocellular basal nucleus subdivisions as revealed by anterogradely transported Phaseolus vulgaris leucoagglutinin. *Brain Res*, 413: 229-250.
- Luscher TF, Raij L, Vanhoutte PM (1987) Endothelium-dependent vascular responses in normotensive and hypertensive Dahl rats. *Hypertension*, 9: 157-163.
- Malamud N (1972) Neuropathology of organic brain syndromes associated with aging. In Gaitz FM (ed): *Advance in Behavioural Biology*. vol. 3: Aging and the Brain. Plenum Press, New York, pp. 63-87.
- Malouf AT (1992) Effect of beta amyloid peptides on neurons in hippocampal slice cultures. *Neurobiol Aging*, 13: 543-551.
- Mandybur TI (1975) The incidence of cerebral amyloid angiopathy in Alzheimer's disease. *Neurology*, 25: 120-126.
- Mann DMA, Jones D, Prinja D, Purkiss MS (1990) The prevalence of amyloid (A4) protein deposits within the cerebral and cerebellar cortex in Down's syndrome and Alzheimer's disease. *Acta Neuropathol*, 80: 318-327.
- Mann DMA, Tucker CM, Yates PO (1987) The topographical distribution of senile plaques and neurofibrillary tangles in the brains of non-demented persons of different ages. *Neuropathol Appl Neurobiol*, 13: 123-139.

- Masters CL, Multhaup G, Simms G, Pottgieser J, Martins RN, Beyreuther K (1985) Neuronal origin of cerebral amyloid: Neurofibrillary tangles of Alzheimer's disease contain the same protein as the amyloid of plaque cores and blood vessels. *Eur Molec Biol Org J*, 4: 2757-2763.
- Mattson MP, Rydel RE, Lieberburg I, Smith-Swintosky VL (1993) Altered calcium signaling and neuronal injury: Stroke and Alzheimer's disease as examples. *Ann New York Acad Sci*, 679: 1-21.
- Mayhan WG, Faraci FM, Heistad DD (1987) Impairment of endothelium-dependent responses of cerebral arterioles in chronic hypertension. *Am J Physiol*, 253: H1435-H1440.
- McKee AC, Kosik KS, Kowall NW (1991) Neuritic pathology and dementia in Alzheimer's disease. *Ann Neurol*, 30: 156-165.
- Mendez MF, Underwood KL, Zander BA, Mastri AR, Sung JH, Frey WH (1992) Risk factors in Alzheimer's disease: A clinico-pathologic study. *Neurology*, 42: 770-775.
- Miller ME, Scott TM (1990) The effect of denervation on endothelium-dependent relaxation to acetylcholine. *Artery*, 17: 233-247.
- Miller MJ, Pinto A, Mullane KM (1987) Impaired endothelium-dependent relaxations in rabbits subjected to aortic coarctation hypertension. *Hypertension*, 10: 164-170.
- Miller RE, Shapiro AP, King E, Ginchereau EH, Hosutt JA (1984) Effect of antihypertensive treatment on the behavioral consequences of elevated blood pressure. *Hypertension*, 6: 202-208.
- Mirra SS, Hart MN, Terry RD (1993) Making the diagnosis of Alzheimer's disease: A primer for practicing pathologists. *Arch Path Lab Med*, 117: 132-144.
- Miyakawa T, Katsuragi S, Yamashita K, Ohushi K (1992) Morphological study of amyloid fibrils and preamyloid deposits in the brain with Alzheimer's disease. *Acta Neuropathol*, 83: 340-346.
- Miyakawa T, Shimoji A, Kuramoto R, Higuchi Y (1982) The relationship between senile plaques and cerebral blood vessels in Alzheimer's disease and senile dementia. Morphological mechanism of senile plaque production. *Virchows Arch (B)*, 40: 121-129.

- Mohs RC, Breitner JCS, Silverman JM, Davis KL (1987) Alzheimer's disease. Morbid risk among first degree relatives approximates 50% by 90 years of age. Arch Gen Psychiatry, 44: 405-408.
- Moncada S, Palmer RM, Higgs EA (1991) Nitric oxide: Physiology, pathophysiology and pharmacology. Pharm Rev, 43: 109-142.
- Montejo de Garcini E, Carrascosa JL, Correias I, Nieto A, Avila J (1988) Tau factor polymers are similar to paired helical filaments of Alzheimer's disease. FEBS Lett, 236: 150-154.
- Mountjoy CQ, Rossor MN, Evans NJR, Reynolds GP, Evans H, Roth M, Iversen LL, Emson P (1986) Biochemical and neuropathological changes in the brain and their correlation to the severity of dementia in Alzheimer's disease. Biol Psychiatry, 21: 1415-1417.
- Mountjoy CQ, Tomlinson BE, Gibson PH (1982) Amyloid and senile plaques and cerebral blood vessels: A semi-quantitative investigation of a possible relationship. J Neurol Sci, 57: 89-103.
- Munoz DG, Wang D (1992) Tangle-associated neuritic clusters. A new lesion in Alzheimer's disease and aging suggests that aggregates of dystrophic neurites are not necessarily associated with beta/A4. Am J Pathol, 140: 1167-1178.
- Nag S, Harik SI (1987) Cerebrovascular permeability to horseradish peroxidase in hypertensive rats: Effects of unilateral locus ceruleus lesion. Acta Neuropathol, 73: 247-253.
- Najlerahim A, Bowen DM (1988) Regional weight loss of the cerebral cortex and some subcortical nuclei in senile dementia of the Alzheimer type. Acta Neuropathol, 75: 509-512.
- Neary D, Snowden JS, Mann DMA, Bowen DM, Sims NR, Nathan B, Yates PO, Davison AN (1986) Alzheimer's disease: A correlative study. J Neurol Neurosurg Psychiatry, 49: 229-237.
- Nelson DO, Boulant JA (1981) Altered CNS neuroanatomical organization of spontaneously hypertensive rats (SHR). Brain Res, 26: 119-130.

- Newman S, Klinger L, Venn G, Smith P, Harrison M, Treasure T (1990) The persistence of neuropsychological deficits twelve months after coronary artery bypass surgery. In Willner AE, Rodewall G (eds): *Impact of Cardiac Surgery on the Quality of Life*. Plenum Press, New York, pp. 173-179.
- Nishimoto I, Okamoto T, Matsuura Y, Takahashi S, Murayama Y, Ogata E (1993) Alzheimer amyloid protein precursor complexes with brain GTP-binding Go. *Nature*, 362: 75-79.
- Ogomori K, Kitamoto T, Tateishi J, Sato Y, Suetsugu M, Abe M (1989) Beta-protein amyloid is widely distributed in the central nervous system of patients with Alzheimer's disease. *Am J Pathol*, 134: 243-251.
- Oltersdorf T, Fritz LC, Schenk DB, Lieberburg I, Johnson-Wood KL, Beattie EC (1989) The secreted form of Alzheimer's precursor protein with the Kunitz domain is protease nexin II. *Nature*, 341: 144-147.
- Oyanagi K, Takahashi H, Wakabayashi K, Ikuta F (1987) Selective involvement of large neurons in the neostriatum of Alzheimer's disease and senile dementia: a morphometric investigation. *Brain Res*, 411: 205-211.
- Pearson RCA, Esiri MM, Hiorns RW, Wilcock GK, Powell TPS (1985) Anatomical correlates of the distribution of the pathological changes in the neocortex in Alzheimer's disease. *Proc Natl Acad Sci USA*, 82: 4531-4534.
- Perry G, Friedman R, Shaw G, Chau V (1987) Ubiquitin is detected in neurofibrillary tangles and senile plaques neurites of Alzheimer disease brains. *Proc Natl Acad Sci USA*, 84: 3033-3036.
- Petrie A (1987) *Lecture Notes on Medical Statistics*. 2nd. ed. Blackwell Scientific Publications, Oxford, pp. 94-114.
- Pike CJ, Burdick D, Walencewicz AJ, Glabe CG, Cotman CW (1993) Neurodegeneration induced by beta-amyloid peptides in vitro: The role of peptide assembly state. *J Neurosci*, 13: 1676-1687.
- Podlisny MB, Stephenson DT, Frosh MP, Lieberburg I, Clemens JA, Selkoe DJ (1992) Synthetic amyloid beta-protein fails to produce specific neurotoxicity in monkey cerebral cortex. *Neurobiol Aging*, 13: 561-567.

- Ponte P, Gonzales-DeWhitt P, Schilling J, Miller J, Hsu D, Greenberg B, Davis K, Wallace W, Lieberburg I, Fuller F, Cordell B (1988) A new A4 amyloid molecular RNA contains a domain homologous to serine proteinase inhibitors. *Nature*, 331: 525-527.
- Prince M, Cullen M, Mann A (1994) Risk factors for Alzheimer's disease and dementia: A case-control study based on the MRC elderly hypertension trial. *Neurology*, 44: 97-104.
- Probst A, Anderton BH, Brion JP, Ulrich J (1989) Senile plaques neurites failed to demonstrate anti-paired helical filament and anti-microtubule associated protein-tau immunoreactive proteins in the absence of neurofibrillary tangles in the neocortex. *Acta Neuropathol*, 77: 430-436.
- Probst A, Brunnschweiler H, Lautenschlager C, Ulrich J (1987) A special type of senile plaque, possibly an initial stage. *Acta Neuropathol*, 74: 133-141.
- Probst A, Lautenschlager C, Brion JP, Anderton BH, Ulrich J (1988) Differential pattern of senile plaque neurites immunoreactivity related to the presence or absence of neurofibrillary tangles in the neocortex. In Ulrich J (ed): *Interdisciplinary Topics on Gerontology*. vol. 25: *Histology and Histopathology of the Aging Brain*. Karger, Basel, pp. 156-172.
- Prohovnik I, Mayeux R, Sackeim HA, Smith G, Stern Y, Alderson PO (1988) Cerebral perfusion as a diagnostic marker of early Alzheimer's disease. *Neurology*, 38: 931-937.
- Raszkiewicz JL, Linville DG, Kervin JF Jr, Wagenaar F, Arneric SP (1992) Nitric oxide synthase is critical in mediating basal forebrain regulation of cortical cerebral circulation. *J Neurosci Res*, 33: 129-135.
- Reich P, Regestein QR, Murawski BJ, DeSilva RA, Lown B (1983) Unrecognized organic mental disorders in survivors of cardiac arrest. *Am J Psychiatry*, 140: 1194-1197.
- Ritter S, Dinh TT (1986) Progressive postnatal dilatation of brain ventricles in spontaneously hypertensive rats. *Brain Res*, 370: 327-332.

- Ritter S, Dinh TT, Stone S, Ross N (1988) Cerebroventricular dilatation in spontaneously hypertensive rats (SHRs) is not attenuated by reduction of blood pressure. *Brain Res*, 450: 354-359.
- Roberts GW, Allsop D, Bruton C (1990) The occult aftermath of boxing. *J Neurol Neurosurg Psychiatry*, 53: 373-378.
- Rocca WA, Amaducci LA, Schoenberg B (1986) Epidemiology of clinically-diagnosed Alzheimer's disease. *Ann Neurol*, 19: 415-424.
- Romanul FCA, Abramowicz A (1964) Changes in brain and pial vessels in arterial border zones. A study of 13 cases. *Arch Neurol*, 11: 40-65.
- Rosenblum WI, Hider A (1988) Negative correlations between parenchymal amyloid and vascular amyloid in hippocampus. *Am J Pathol*, 130: 532-536.
- Roth M (1985) Evidence on the possible heterogeneity of Alzheimer's disease and its bearing on future inquiries into etiology and treatment. In Butler RN, Bearn AG (eds): *The Aging Process: Therapeutic Implications*. Raven Press, New York, pp. 251-271.
- Rozemuller AJM, Roos RAC, Bots GTAM, Kamphorst W, Eikelenboom P, Van Nostrand WE (1993) Distribution of beta/A4 protein and amyloid precursor protein in hereditary cerebral hemorrhage with amyloidosis-Dutch type and Alzheimer's disease. *Am J Pathol*, 142: 1449-1457.
- Rudelli RD, Ambler MW, Wisniewski HM (1984) Morphology and distribution of Alzheimer neuritic (senile) and amyloid plaques in striatum and diencephalon. *Acta Neuropathol*, 64: 273-281.
- Salerno JA, Murphy DGM, Horwitz B, De Carli C, Haxby JV, Rapoport SI, Schapiro MB (1992) Brain atrophy in hypertension. A volumetric magnetic resonance imaging study. *Hypertension*, 20: 340-348.
- Scheibel AB (1987) Alterations of the cerebral capillary bed in the senile dementia of Alzheimer. *Ital J Neurol Sci*, 8: 457-463.
- Scott TM, Chafe L (1994a) The involvement of perivascular innervation in acetylcholine-induced endothelium-dependent vascular relaxation in the rat superior

- mesenteric arterial bed (to be published in Blood Vessels).
- Scott TM, Chafe L (1994b) The involvement of CGRP in acetylcholine-induced vascular relaxation (to be published in Artery).
- Scott TM, Drodge KH, Foote J (1992) Peptidergic nerve involvement in the control of endothelium-dependent vascular relaxation. *Artery*, 19: 211-224.
- Scott TM, Pang SC (1983) The correlation between the development of sympathetic innervation and the development of media hypertrophy in jejunal arteries in normotensive and spontaneously hypertensive rats. *Auton Nerv Sys*, 8: 25-32.
- Scott TM, Robinson J, Foote J (1986) Development of substance-P-like immunoreactive innervation of the mesenteric vascular bed in normotensive and hypertensive rats. In Henry JL, Couture R, Cuello AC, Pelletier G, Quirion R, Regoli D (eds): *Substance P and Neurokinins*. Springer Verlag, New York, pp. 217-219.
- Selkoe DJ (1991) The molecular pathology of Alzheimer's disease. *Neuron*, 6: 487-498.
- Selkoe DJ, Abraham CR, Podlisny B, Duffy LK (1986) Isolation of low-molecular weight proteins from amyloid plaque fibers in Alzheimer's disease. *J Neurochem*, 146: 1820-1834.
- Seltzer B, Sherwin I (1983) A comparison of clinical features in early- and late-onset primary degenerative dementia: one entity or two. *Arch Neurol*, 40: 143-146.
- Shaw PJ, Bates D, Cartlidge NE, French JM, Heaviside D, Julian DG, Shaw DA (1987) Neurologic and neuropsychological morbidity following major surgery: Comparison of coronary artery bypass and peripheral vascular surgery. *Stroke*, 18: 700-707.
- Shaw PJ, Bates D, Cartlidge NE, Heaviside D, Julian DG, Shaw DA (1985) Early neurologic complications of coronary artery bypass surgery. *Br Med J*, 291: 1384-1387.
- Shibayama H, Kitoh J (1978) Electron-microscopic structure of the Alzheimer's neurofibrillary changes in a case of atypical senile dementia. *Acta Neuropathol*, 41: 229-234.

- Sparks DL, Hunsaker JC, Scheff SW, Kryscio RJ, Henson JL, Markesbery WR (1990) Cortical senile plaques in coronary artery disease, aging and Alzheimer's disease. *Neurobiol Aging*, 11: 601-607.
- Sparks DL, Liu H, Scheff SW, Coyne CM, Hunsaker JC (1993) Temporal sequence of plaque formation in the cerebral cortex of non-demented individuals. *J Neuropathol Exp Neurol*, 52: 135-142.
- Stein-Behrens B, Adams K, Yeh M, Sapolsky R (1992) Failure of beta-amyloid protein fragment 25-35 to cause hippocampal damage in the rat. *Neurobiol Aging*, 13: 577-579.
- Stern Y, Mayeux R, Sano M, Hauser WA, Bush T (1987) Predictors of disease course in patients with probable Alzheimer's disease. *Neurology*, 37: 1649-1653.
- Stewart PA, Hayakawa K, Akers MA, Vinters HV (1992) A morphometric study of the blood-brain barrier in Alzheimer's disease. *Lab Invest*, 67: 734-742.
- Stewart PA, Magliocco M, Hayakawa K, Farrell CL, del Maestro RF, Girvin J, Kaufmann JCE, Vinters HV, Gilbert J (1987) A quantitative analysis of blood-brain barrier ultrastructure in the aging human. *Microvasc Res*, 33: 270-282.
- Suenaga T, Hirano A, Llena JF, Ksiezak-Reding H, Yen SH, Dickson DW (1990) Modified Bielschowsky and immunohistochemical studies on cerebellar plaques in Alzheimer's disease. *J Neuropathol Exp Neurol*, 49: 31-40.
- Tabaton M, Mandybur TI, Perry G, Onorato M, Autilio-Gambetti L, Gambetti P (1989) The widespread alteration of neurites in Alzheimer's disease may be unrelated to amyloid deposition. *Ann Neurol*, 26: 771-778.
- Tabaton M, Whitehouse PJ, Perry G, Davies P, Autilio-Gambetti L, Gambetti P (1988) Alz50 recognizes abnormal filaments in Alzheimer's disease and progressive supranuclear palsy. *Ann Neurol*, 24: 407-413.
- Tajima A, Hans FJ, Livingstone D, Wei L, Finnegan W, De Maro J, Fenstermacher J (1993) Smaller local brain volumes and cerebral atrophy in spontaneously hypertensive rats. *Hypertension*, 21: 105-111.

- Takahashi N, Iwatsubo T, Nakano I, Machinami R (1992) Focal appearance of cerebellar torpedoes associated with discrete lesions in the cerebellar white matter. *Acta Neuropathol*, 84: 153-156.
- Tan N, Mastaglia FL, Masters CL, Beyreuther K, Kakulas BA (1988) Amyloid A4 protein deposition in brain in progressive supranuclear palsy (psp). *Alzheimer Dis Assoc Disord*, 2: 264.
- Tanzi RE, McClatchey AI, Lamperti ED, Villa-Komaroff L, Gusella JF, Neve RL (1988) Protease inhibitor domain encoded by an amyloid protein precursor mRNA associated with Alzheimer's disease. *Nature*, 331: 528-530.
- Tanzi RE, St George-Hyslop PH, Gusella JF (1989) Molecular genetic approaches to Alzheimer's disease. *Trends Neurosci*, 12: 152-158.
- Terry RD, Hansen LA, DeTeresa R, Davies P, Tobias H, Katzman R (1987) Senile demntia of Alzheimer type without neocortical fibrillary tangles. *J Neuropathol Exp Neurol*, 46: 262-268.
- Terry RD, Masliah E, Salmon DP, Butters N, DeTeresa R, Hill R, Hansen LA, Katzman R (1991) Physical basis of cognitive alterations in Alzheimer's disease: Synapse loss is the major correlate of cognitive impairment. *Ann Neurol*, 30: 572-580.
- Terry RD, Wisniewski HM (1970) The ultrastructure of the neurofibrillary tangle and the senile plaque. In Wolstenholme GEW, O'Connor M (eds): *Alzheimer's Disease and Related Conditions*. A Ciba Foundation Symposium. J and A Churchill, London, np. 145-168.
- Tomlinson BE (1982) Plaques, tangles and Alzheimer's disease. *Psychol Med*, 12: 449-459.
- Tomlinson BE (1992) Ageing and the dementias. In Duchen LW, Adams JH (eds): *Greenfield's Neuropathology*. 5th. ed. Oxford University Press, New York, pp. 1284-1410.
- Tomlinson BE, Blessed G, Roth M (1968) Observations on the brains of non-demented old people. *J Neurol Sci*, 7: 331-356.
- Tomlinson BE, Blessed G, Roth M (1970) Observations on the brains of demented old people. *J Neurol Sci*, 11: 205-242.

- Tomlinson BE, Kitchener D (1972) Granulovacuolar degeneration of hippocampal pyramidal cells. *J Pathol*, 106: 165-185.
- Tresch D, Folstein M, Robins P, Hazzard W (1985) Prevalence and significance of cardiovascular disease and hypertension in elderly patients with dementia and depression. *J AM Geriatr Soc*, 33: 530-537.
- Van Deurs B (1976) Observations on the blood-brain barrier in hypertensive rats with particular reference to phagocytic pericytes. *J Ultrastruct Res*, 56: 65-77.
- Van Hoesen GW, Hyman BT (1990) Hippocampal formation: Anatomy and the pattern of pathologies in Alzheimer's disease. In Storm-Mathisen J, Zimmer J, Ottersen OP (eds): *Progress in Brain Research*. vol. 83: Understanding the Brain Through the Hippocampus. Elsevier, New York, pp. 445-457.
- Van Norstrand WE, Wagner SL, Suzuki M, Choi BH, Farrow JS, Geddes JW (1989) Protease nexin-II, a potent antichymotrypsin, shows identity to amyloid beta-protein precursor. *Nature*, 341: 546-549.
- Vickers JC, Delacourte A, Morrison JH (1992) Progressive transformation of the cytoskeleton associated with normal aging and Alzheimer's disease. *Brain Res*, 594: 273-278.
- Wilcock GK, Esiri MM, Bowen DM, Hughes AO (1988) The differential involvement of subcortical nuclei in senile dementia of the Alzheimer type. *J Neurol Neurosurg Psychiatry*, 51: 842-849.
- Wilcock GK, Esiri MM, Bowen DM, Smith CT (1982) Correlation of cortical choline acetyltransferase activity with the severity of dementia and histological abnormalities. *J Neurol Sci*, 57: 407-417.
- Winquist RJ, Bunting PB, Baskin EP, Wallace AA (1984) Decreased endothelium-dependent relaxation in New Zealand genetic hypertensive rats. *J Hypertens*, 2: 541-545.
- Wisniewski HM, Kozlowski PB (1982) Evidence for blood-brain barrier changes in senile dementia of the Alzheimer type (SDAT). *Ann NY Acad Sci*, 396: 119-129.
- Wisniewski HM, Narang HK, Terry RD (1976) Neurofibrillary tangles of paired helical filaments. *J Neurol Sci*, 27: 173-181.

- Wisniewski HM, Wen GY, Kim KS (1989) Comparison of four staining methods on the detection of neuritic plaques. *Acta Neuropathol*, 78: 22-27.
- Wisniewski KE, Jervis GA, Mortez RC, Wisniewski HM (1979) Alzheimer neurofibrillary tangles in diseases other than senile and presenile dementia. *Ann Neurol*, 5: 288-294.
- Wisniewski KE, Wisniewski HM, Wen GY (1985) Occurrence of neuropathological changes and dementia of Alzheimer's disease in Down's syndrome. *Ann Neurol*, 17: 278-282.
- Wolozin BL, Davies P (1987) Alzheimer-related neuronal protein A68: Specificity and distribution. *Ann Neurol*, 22: 521-526.
- Yagashita S, Itoh Y, Wang N, Amano N (1981) Reappraisal of the fine structure of Alzheimer's neurofibrillary tangles. *Acta Neuropathol*, 54: 239-246.
- Yamada M, Tsukagoshi H, Otomo E, Hayakawa M (1987) Cerebral amyloid angiopathy in the aged. *J Neurol*, 234: 371-376.
- Yamaguchi S, Hirai S, Morimatsu M, Shoji M, Harigaya Y (1988a) Diffuse type of senile plaques in the brains of Alzheimer-type dementia. *Acta Neuropathol*, 77: 113-119.
- Yamaguchi S, Hirai S, Morimatsu M, Shoji M, Ihara Y (1988b) A variety of cerebral amyloid deposits in the brains of the Alzheimer-type dementia demonstrated by beta protein immunostaining. *Acta Neuropathol*, 76: 541-549.
- Yamaguchi S, Hirai S, Morimatsu M, Shoji M, Nakazato Y (1989) Diffuse type of senile plaques in the cerebellum of Alzheimer-type dementia demonstrated by beta protein immunostain. *Acta Neuropathol*, 77: 314-319.
- Yamazaki T, Yamaguchi H, Nakazato Y, Ishiguro K, Kawarabayashi T, Hirai S (1992) Ultrastructural characterization of cerebellar diffuse plaques in Alzheimer's disease. *J Neuropathol Exp Neurol*, 51: 281-286.
- Yankner BA, Duffy LK, Kirschner DA (1990) Neurotrophic and neurotoxic effects of amyloid beta protein: Reversal by tachykinin neuropeptides. *Science*, 250: 279-282.

Zlokovic BV, Ghiso J, Mackic JB, McComb JG, Weiss MH, Frangione B (1993) Blood-brain barrier transport of circulating Alzheimer's amyloid beta. *Biochem Biophys Res Comm*, 197: 1034-1040.



