



Tubedown-1 (Tbdn-1) suppression in oxygen-induced retinopathy and in retinopathy of prematurity

Robert L. Gendron,¹ William V. Good,² Ewa Miskiewicz,¹ Stephanie Tucker,¹ Dale L. Phelps,^{3,4} H el ene Paradis¹

¹Division of Basic Medical Sciences, Department of Medicine, Memorial University of Newfoundland, St. John's, Newfoundland, Canada; ²Smith Kettlewell Eye Research Institute, San Francisco, CA; Departments of ³Pediatrics and ⁴Ophthalmology, University of Rochester School of Medicine and Dentistry, Rochester, NY

Purpose: Identification of unique proteins involved in retinopathy of prematurity (ROP) may facilitate new and more effective diagnostic tools and molecular-based treatments for ROP. Tubedown-1 (Tbdn-1), a novel homeostatic protein which copurifies with an acetyltransferase activity, is expressed in normal retinal endothelium and is specifically suppressed in retinal endothelial cells from patients with proliferative diabetic retinopathy. Furthermore, recent *in vivo* knock-down studies in mice have revealed that Tbdn-1 is important for retinal blood vessel homeostasis and for preventing retinal neovascularization in adults. The purpose of the present study was to determine if the expression pattern of Tbdn-1 is altered during oxygen-induced retinal neovascularization in mice and in a specimen of stage 3 human ROP.

Methods: Specimens of oxygen-induced retinal neovascularization in mice, and a single specimen of active stage 3 ROP were studied by immunohistochemistry and digital image analysis using antibodies raised against Tbdn-1 and other blood vessel markers.

Results: The pattern of Tbdn-1 expression during the course of oxygen-induced retinal neovascularization in mice suggests a regulating role in neonatal retinopathy. Retinal lesions from oxygen-induced retinal neovascularization in mice display suppression of retinal endothelial Tbdn-1 protein expression in conjunction with an increase in expression of proliferating cell nuclear antigen (a marker of proliferation) and α smooth muscle actin (a marker of myofibroblastic cells). Abnormal blood vessels within vitreoretinal neovascular lesions in a human specimen of active stage 3 ROP did not show Tbdn-1 protein expression.

Conclusions: These results suggest that the loss of retinal endothelial Tbdn-1 expression may be a contributing factor in retinal blood vessel proliferation in ROP.

Retinopathy of prematurity (ROP) remains a leading cause of vision impairment in children in the United States [1]. The need for investigating new molecular-based therapies for ROP is exemplified by the recently completed Early Treatment for ROP study (ETROP) [2]. That trial demonstrated that early treatment for high risk ROP resulted in better outcomes than traditional timing, yet 9.1% of the eyes in the Early Treatment arm still experienced retinal detachments or similar complications leading to severe vision loss. Thus, even with more optimally timed treatment, thousands of children worldwide are still blinded by the disease. In ROP, retinal blood vessels fail to develop to the peripheral areas of the retina, and a demarcation zone is thus created, dividing vascularized from avascular retina [3,4]. In mild cases of ROP, the demarcation appears as a line, but in severe cases, neovascularization occurs in the demarcation line or area. This neovascularization may further progress to cicatricial changes, which, in turn, can eventually lead to either a partial or total retinal detachment [4]. Since current treatments involve ablation of peripheral retina, and because infants are still blinded by the disease despite adequate treatment, further work is needed to explore new molecular-based therapies for ROP.

The molecular sequence of events leading to ROP is complex. The transition from an *in utero* arterial oxygen tension (PaO_2) of 30 or less to an extrauterine PaO_2 of 80 or more occurs within minutes of birth. The avascular regions of a premature infant's partially vascularized retina mount a neovascularization response to counter the endarterial vasoconstriction occurring as a result of increased systemic oxygenation [5]. Several growth and transcription factors, especially those involved in the responses to hypoxia and hyperoxia such as vascular endothelial growth factor (VEGF) and hypoxia-inducible factor (HIF-1 α), have been described as potential angiogenic regulators of ROP [3,4,6,7]. Low serum levels of insulin-like growth factor (IGF-1) have been linked to the development of ROP [8]. IGF-1 is important for retinal vascular development and regulates VEGF-induced survival signaling pathway in retinal endothelial cells which most likely plays a key role in the neovascularization seen in ROP [7]. Other proteins such as platelet-derived growth factor BB (PDGF-BB), the angiopoietins (Ang-1 and Ang-2), and the Tie receptors (Tie-1 and Tie-2) are important molecules for controlling development of the vascular architecture and may play key roles in retinal neovascularization [9-11]. Any or all of these molecules and related processes may play a role in the pathogenesis of human ROP.

Work on molecular mechanisms in the ROP disease process have focused on growth factors, but proteins homeostatic to retinal blood vessels could also be important in averting the

Correspondence to: Robert L. Gendron, Division of Basic Medical Sciences, Department of Medicine, Memorial University of Newfoundland, St. John's, NL, A1B 3V6, Canada; Phone: (709) 777-8554; FAX: (709) 777-8619; email: rgendron@mun.ca

disease process in ROP. One such protein is Tubedown-1 (Tbdn-1), present in stable retinal vascular beds. Tbdn-1 is a mammalian homolog of the yeast acetyltransferase subunit Nat1 that is regulated during vascular development [12]. While Tbdn-1 expression is restricted to few vascular beds in adults including normal ocular endothelial cells, atrial endocardium, blood vessels of regressing ovarian follicles, and bone marrow capillaries, Tbdn-1 expression is suppressed in retinal blood vessels in patients with proliferative diabetic retinopathy (PDR) [12,13]. Our laboratories have recently generated a binary antisense *Tbdn-1* (*Astbdn-1*) transgenic mouse model driven by the *Tie-2* pan-endothelial promoter, which enables conditional knockdown of Tbdn-1 protein expression in endothelial cells. *Tbdn-1* knockdown animals display a phenotype that is restricted to the retina and characterized by neovascular proliferative retinopathy [14]. Our *Tbdn-1* knockdown model has provided in vivo evidence for the requirement of *Tbdn-1* expression for the maintenance of normal retinal vascular homeostasis [14]. In the present study, we have addressed whether Tbdn-1 protein expression becomes altered in oxygen-induced retinopathy in mice and have assessed the state of Tbdn-1 expression in a case of stage 3 neovascular ROP in humans.

METHODS

Oxygen-induced retinopathy in mice: All mouse tissues used in this study were obtained from wild type C57BL/6 mice using procedures adherent to the Canadian Council on Animal Care. Neonatal mice were reared in normoxic conditions or in modified ambient oxygen concentrations (75% oxygen) for five days from postnatal (P) day 7 followed by normoxia for periods of time designed to induce retinal neovascularization as previously described [15]. In our studies, eyes from 4 to 14 mice harvested at each point from P14 through P26 of normoxia or hyperoxia were analyzed by immunohistochemistry. Normal and hyperoxia-treated mouse eyes were fixed in 4% paraformaldehyde, embedded in paraffin, and processed for histology and immunohistochemistry as previously described in the literature [14,16]. Sections were stained for morphological analysis with hematoxylin and eosin (H&E) or for immunohistochemical analysis with different antibodies as will be described. Antibodies used for immunohistochemistry included the following: Mouse anti-Tbdn-1 serum MS.C10-20TD [14], the mouse monoclonal anti- α smooth muscle actin (ASMA) antibody (dilution of 1/100; Sigma Immunochemicals, St. Louis, MO), and rabbit anti-proliferating cell nuclear antigen (PCNA; diluted 1:25, Santa Cruz Biotechnology, Inc., Santa Cruz, CA). Mouse antibodies were applied following a 30 min incubation in rabbit antimouse blocking preparation. The sections were rinsed in the appropriate concentration of TBS (10 mM Tris-HCl, pH 7.6, 150 mM NaCl), and reactions were developed using conjugated species-specific secondary antibodies. Red color reactions for Tbdn-1 and ASMA staining were generated using naphthol-AS-MX phosphate in the presence of fast red and levamisole (to block endogenous tissue alkaline phosphatase activity). Dark brown color reactions for PCNA staining were gener-

ated using diaminobenzidine (DAB) in the presence of hydrogen peroxide (sections had been pretreated with hydrogen peroxide to quench endogenous peroxidase activity). Reacted sections were lightly counterstained using a 0.5% aqueous solution of methyl green, rinsed in water, dried, and mounted in Permount (Fisher, Pittsburgh, PA).

Immunohistochemistry of Tbdn-1 expression in human ROP: Tbdn-1 expression was analyzed in one eye specimen from a premature infant with stage 3 ROP. The ROP case was as follows: 471 g birth weight, 27.5 weeks at birth, small for gestational age twin. The patient was examined regularly for ROP from age five weeks to the time of death at 48.5 weeks. One week before death, ROP was still active, showing zone II, stage 3 in both eyes without plus disease. The expression of Tbdn-1 in the ROP specimen was compared to Tbdn-1 staining in sections from an eye from a 19-week human fetus without ROP and to the level of staining found in two previous studies of normal human retinal blood vessels [13,16]. Research on human specimens followed the tenets of the Declaration of Helsinki at all times. All human eye tissue specimens were obtained and studied under the approval of the Institutional Review Boards of the authors' institutions (Smith Kettlewell Eye Research Institute, San Francisco, CA; University of Rochester, Rochester, NY; and Memorial University of Newfoundland, St. John's, Canada). Eyes from the 19-week human fetus without ROP and eyes from the ROP patient were procured at autopsy. The eyes then were fixed in formalin, processed, and embedded in paraffin blocks, and sectioned. Sections were deparaffinized, rehydrated, and subjected to immunohistochemistry for Tbdn-1 expression using Ab1272 antibody and for α -tubulin using an anti- α -tubulin specific mouse monoclonal antibody (Sigma Immunochemicals). Immunohistochemistry using the anti-Tbdn-1 chicken IgY antibody (Ab1272) as described in the literature [12,13,16]. Red color reactions for Tbdn-1 and for α -tubulin staining were generated using aminoethylcarbazole (AEC) in the presence of hydrogen peroxide (sections had been pretreated with hydrogen peroxide to quench endogenous peroxidase activity). Reacted sections were not counterstained (in order to be able to detect low staining levels in Tbdn-1 cases), rinsed in water, dried, and mounted in Permount (Fisher, Pittsburgh, PA).

Data collection and analysis: From P14-P26 normoxia-reared neonatal mice (n=31) or P14-P26 modified ambient oxygen-reared neonatal mice (n=54), approximately 100 sections per eye were prepared, registered, and stored in serial or adjacent order. Every 15th section was stained with H&E to verify normal morphology in the controls and to map the retinal pathology in hyperoxia-treated mice. Tbdn-1 and marker analysis (ASMA, PCNA) was performed in at least three separate experiments on sections serial to those containing retinal lesions from hyperoxia-reared mice (as determined by H&E staining) and sections from the same area of the retina in control normoxia-reared mice. All sections were viewed and photographed using a Zeiss Photomicroscope system (Carl Zeiss Canada Ltd., Toronto, Canada) interfaced with a QImaging digital video camera attachment. Between three to six repre-

representative digital images from normoxia controls and hyperoxia-treated mice were processed with Improvision Openlab (version 3) and Adobe Photoshop (version 7) software for quantitation of the staining. Values were expressed as the mean percentage of the control \pm standard error (SEM in percentage). Data were statistically analyzed by Student's t-test. Intensity of Tbdn-1 staining in retinal blood vessels and background staining (from the inner plexiform layer area) was measured by determining red color intensity using Openlab software. Background measurements, which were similar for all specimens examined, were subtracted from Tbdn-1 retinal blood vessel staining measurements. ASMA (red) and PCNA (brown) staining intensity was measured using the magic wand and pixels measurement tool of the histogram function in Adobe Photoshop as described previously [17]. Staining intensity was

expressed in means of pixels per unit area (\pm SEM) where unit areas are defined as micrographs of equivalent dimension taken at equivalent magnification and light intensity. For ASMA and PCNA staining, not all control retina sections contained ASMA- or PCNA-expressing cells. As a result, the numbers for quantitative analysis were, respectively, limited to the numbers described in the figure legends. Micrographs shown in Figure 1 and Figure 2 are representative experiments of data quantified and presented in Figure 3 and Figure 4, respectively.

RESULTS

Tbdn-1 expression is suppressed during oxygen-induced retinopathy: Tbdn-1 has been characterized as a retinal endothelial homeostatic factor that blocks or prevents retinal neovascularization in an adult mouse model [14]. To charac-

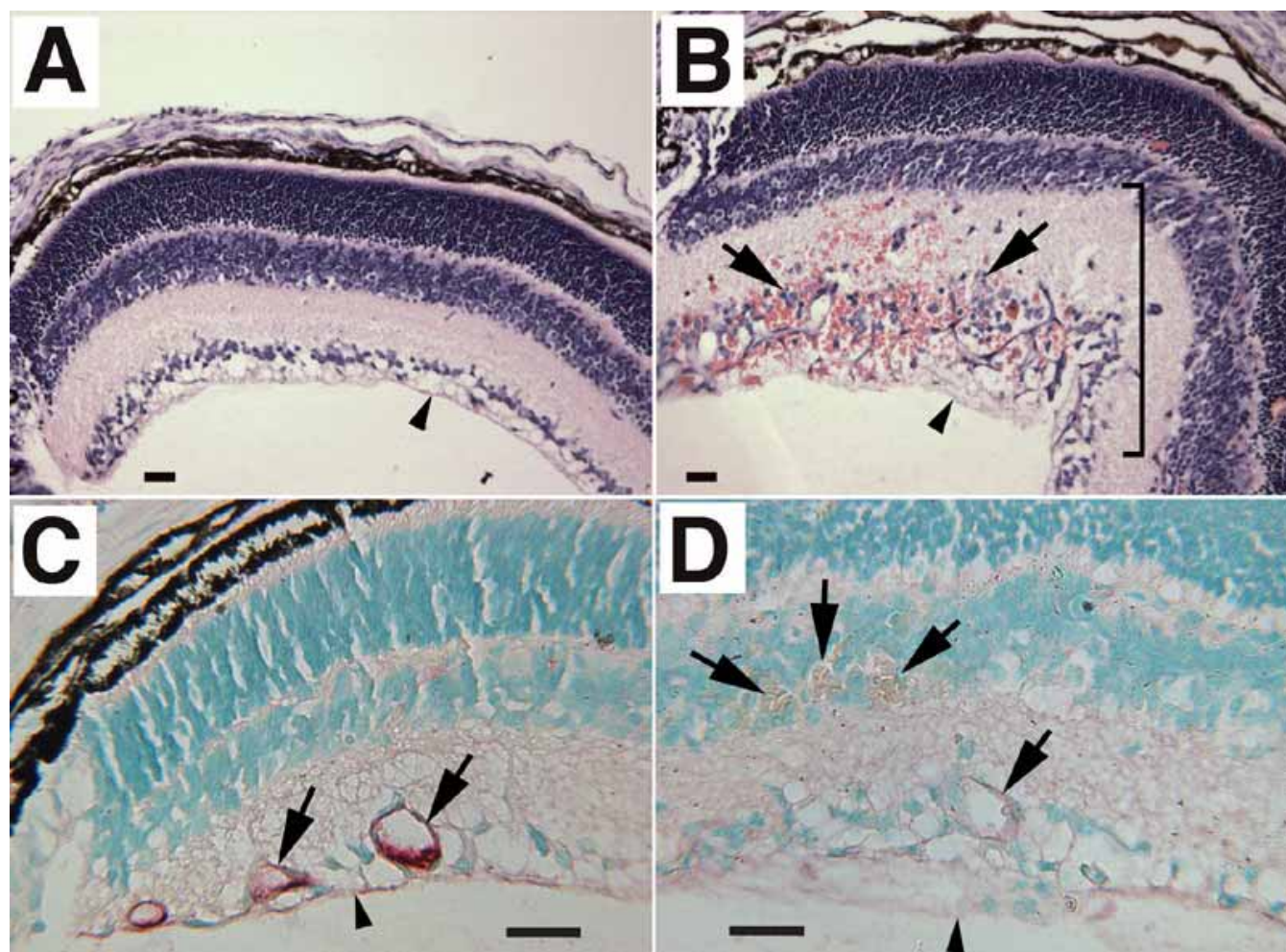


Figure 1. Analysis of Tbdn-1 expression in oxygen-induced retinopathy in mice. **A:** Control normoxia-reared mice do not show any retinal pathology. **B:** In striking contrast, hyperoxia-reared mice present retinal lesions displaying retinal neovascularization, fibrovascular growth, and large areas with blood vessel leakage. Arrows point to retinal blood vessels, and the bracket indicates a large area of retinal lesion. Tbdn-1 immunohistochemical analysis of retinal vessels in sections of control normoxia-reared (**C**) show robust Tbdn expression in controls (red staining seen in vessels marked with arrows) and almost complete loss of retinal blood vessel Tbdn expression in hyperoxia-reared (**D**) neonatal mice (little to no red staining seen in vessels indicated with arrows). In all panels, day of analysis is P17 and vitreous body is oriented at bottom of panel. Scale bars represent 25 μ m. The retinal inner limiting membrane is indicated by small arrowheads. Original magnification was 100x in **A,B** and 250x in **C,D**. Counterstain in panels **A,B** is hematoxylin and eosin. Counterstain in panels **C,D** is methyl green. Micrographs shown are representative experiments.

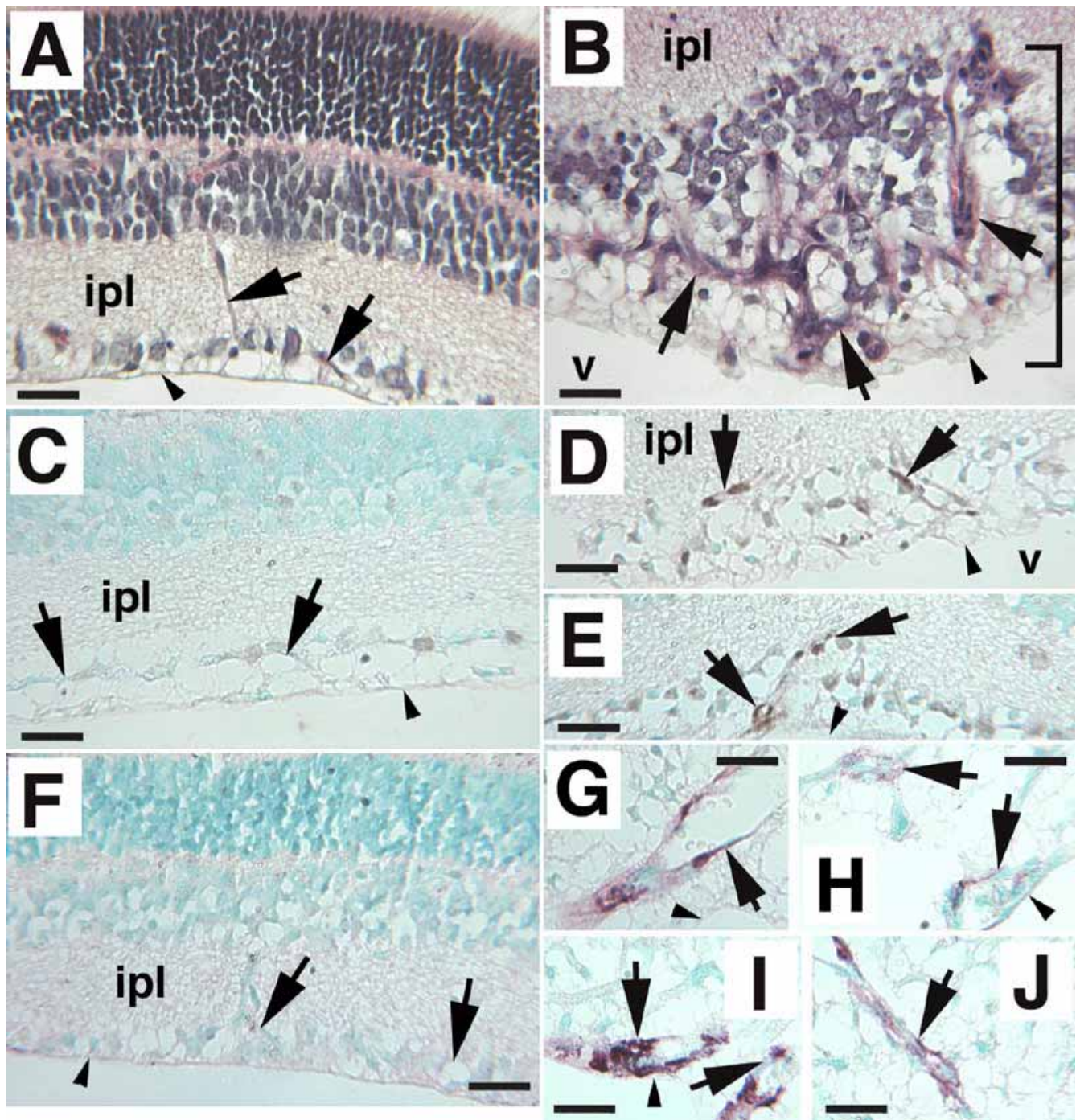


Figure 2. Analysis of blood vessel marker expression in oxygen-induced retinopathy in mice. **A:** Control normoxia-reared mice showing no retinal pathology. The arrows point to normal retinal blood vessels from a control mouse. **B:** Hyperoxia-reared mice present large abnormal distended vessels extending along the retina and also exhibit fibrovascular growth. Arrows point to retinal blood vessels, and the bracket indicates a retinal lesion. Nuclear expression of proliferating cell nuclear antigen (PCNA; dense nuclear brown stain, arrows) is upregulated in endothelial cells in cross-sections of retinal blood vessels within the retinal lesions of oxygen-induced animals (**D,E**), while control animals show low levels of PCNA expression (**C**). α smooth muscle actin (ASMA) immunostaining (brown reddish staining, arrows) of fibrovascular retinal lesion from oxygen-induced mice (**G-J**) reveals large abnormal vessels containing myofibroblast cells (arrows) while ASMA expression is not detected in blood vessels of most of the normal control sections analyzed (arrows in **F**, in which a representative specimen is shown). Low ASMA staining was detected in a total of two retinal blood vessels within three sections of 10 normoxia control retinas analyzed (Figure 4). In all panels, day of analysis is P15, and vitreous body is oriented at bottom of panel. The vitreous (v) and inner plexiform layer (ipl) are identified for orientation. Scale bars represent 25 μ m. The retinal inner limiting membrane is indicated by small arrowheads. Original magnification was 250x. Counterstain in panels **A,B** is hematoxylin and eosin. Counterstain in panels **C-J** is methyl green. Micrographs shown are representative experiments.

terize Tbdn-1 expression in neonatal retinal neovascularization, we studied the oxygen-induced retinopathy mouse model. Retinal neovascularization in the mouse oxygen-induced retinopathy model has previously been reported to be maximal between P17-P21 [15]. To determine if Tbdn-1 may be involved in oxygen-induced retinopathy, we rationalized that an assessment of Tbdn-1 expression between P14 and P26 would be most informative in evaluating if Tbdn-1 could play a role in neonatal retinal neovascularization since changes in Tbdn-1 expression might precede maximal neovascularization. Neonatal wild type C57BL/6 mice reared in hyperoxia revealed a phenotype consistent with previous reports [15] and characterized by the development of retinal lesions displaying retinal thickening, retinal membranes with neovascularization and fibrovascular growth (Figure 1B). Retinal pathology was observed as early as P14 and was maximal from P17 to P21. At postnatal age P26, most of the retinal neovascularization had regressed but a few areas still displayed pathology. In contrast, normoxia-reared control mice do not show any ocular pathology (Figure 1A).

In order to spatially and temporally quantitate changes in expression of retinal endothelial Tbdn-1 during oxygen-induced retinal neovascularization, Tbdn-1 immunostaining and methodology was used to measure immunohistochemical chromogen intensity in retinal blood vessels. Neonatal mice reared in elevated levels of oxygen showed significant decreases in expression of Tbdn-1 in proliferative retinal blood vessels of retinal lesions at all times examined (P14-P26) as compared to retinal blood vessels of age-matched control normoxia reared mice (Figure 1C,D, Figure 2). Quantitation of Tbdn-1 immunostaining in the vessels was carried out at three time points: P14-P16 for the initial neovascularization period, P17-P21 for the maximal neovascularization period, and P26 for the final or late neovascularization period. Quantitation of Tbdn-1 immunostaining was also divided in the oxygen-induced retinas into areas of distinct retinal lesions and the areas between these called “non-lesions”. Quantitation of Tbdn-1 immunostaining in vessels of retinal lesions prior to (P14-P16), during (P17-P21), and shortly after maximal retinal neovascularization (P26) revealed that Tbdn-1 levels were

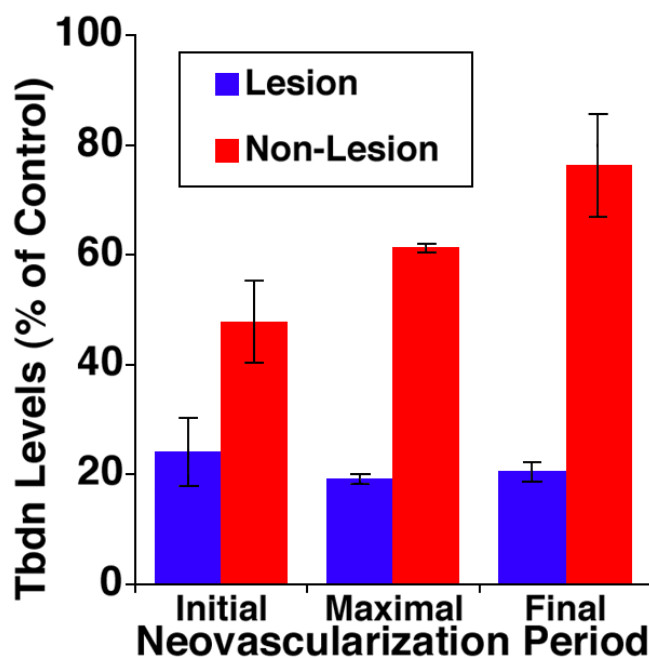


Figure 3. Quantitative analysis of Tbdn-1 expression in oxygen-induced retinopathy in mice. Analysis of Tbdn-1 expression levels from initial period (P15), maximal period (P17), and final period of neovascularization (P26) in lesion areas of the retina (blue bars) compared to non-lesional areas of the retina (red bars) in hyperoxia-reared mice expressed as a percentage of the values for the control normoxia-reared mice; error bars represent SEM. “Lesion” refers to areas within retinal lesions displaying neovascularization, while “Non-Lesion” represents areas outside retinal lesions displaying no neovascularization. Bars represent means of 3 to 6 representative digital images from normoxia controls and hyperoxia-treated mice. All but the non-lesion final neovascularization period (P26; $p=0.26$) were significantly different from controls ($p<0.04$).

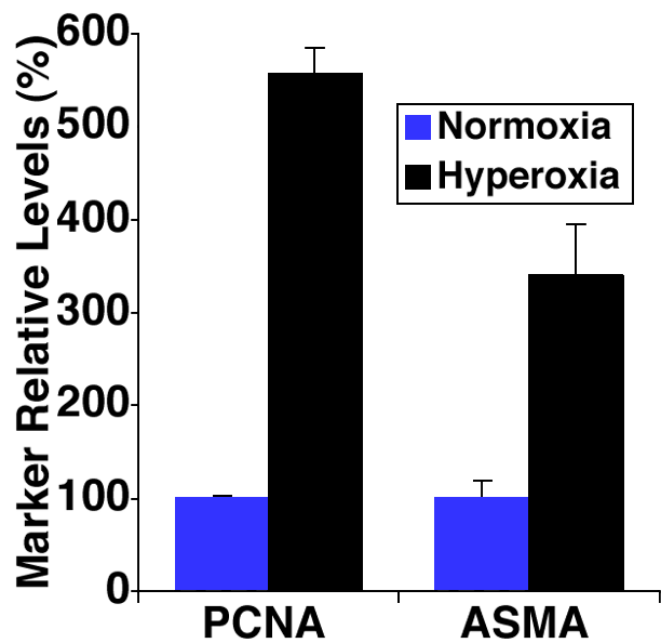


Figure 4. Quantitative analysis of blood vessel marker expression in oxygen-induced retinopathy in mice. Endothelial nuclear expression of proliferating cell nuclear antigen (PCNA) and blood vessel wall expression of α smooth muscle actin (ASMA) in normoxia controls (blue bars) compared to PCNA and ASMA expression in retinal lesions of oxygen-induced animals (black bars) assessed at P15. For PCNA, there were 3 controls and 3 hyperoxic mice. For ASMA, there were 2 controls and 5 hyperoxic mice. Low ASMA staining was detected in a total of two retinal blood vessels within three sections of 10 normoxia control retinas analyzed. Error bars represent SEM. Both PCNA and ASMA expression in hyperoxia-reared were significantly different from control values ($p<0.01$).

reduced to 24% to 19% of control (Figure 2). Interestingly, Tbdn-1 expression in retinal blood vessels in areas outside the retinal lesions was also significantly suppressed prior to (P14-16: 48% of control) and during maximal neovascularization (P17-P21: 60% of control) compared to normoxia-reared mice

(Figure 2). Therefore, Tbdn-1 suppression outside the retinal lesions was not as pronounced as the suppression observed in areas of retinal pathology (Figure 2). In contrast, at P26 in the hyperoxia-reared mice, Tbdn-1 levels outside the retinal lesions did not differ significantly from control room air-reared

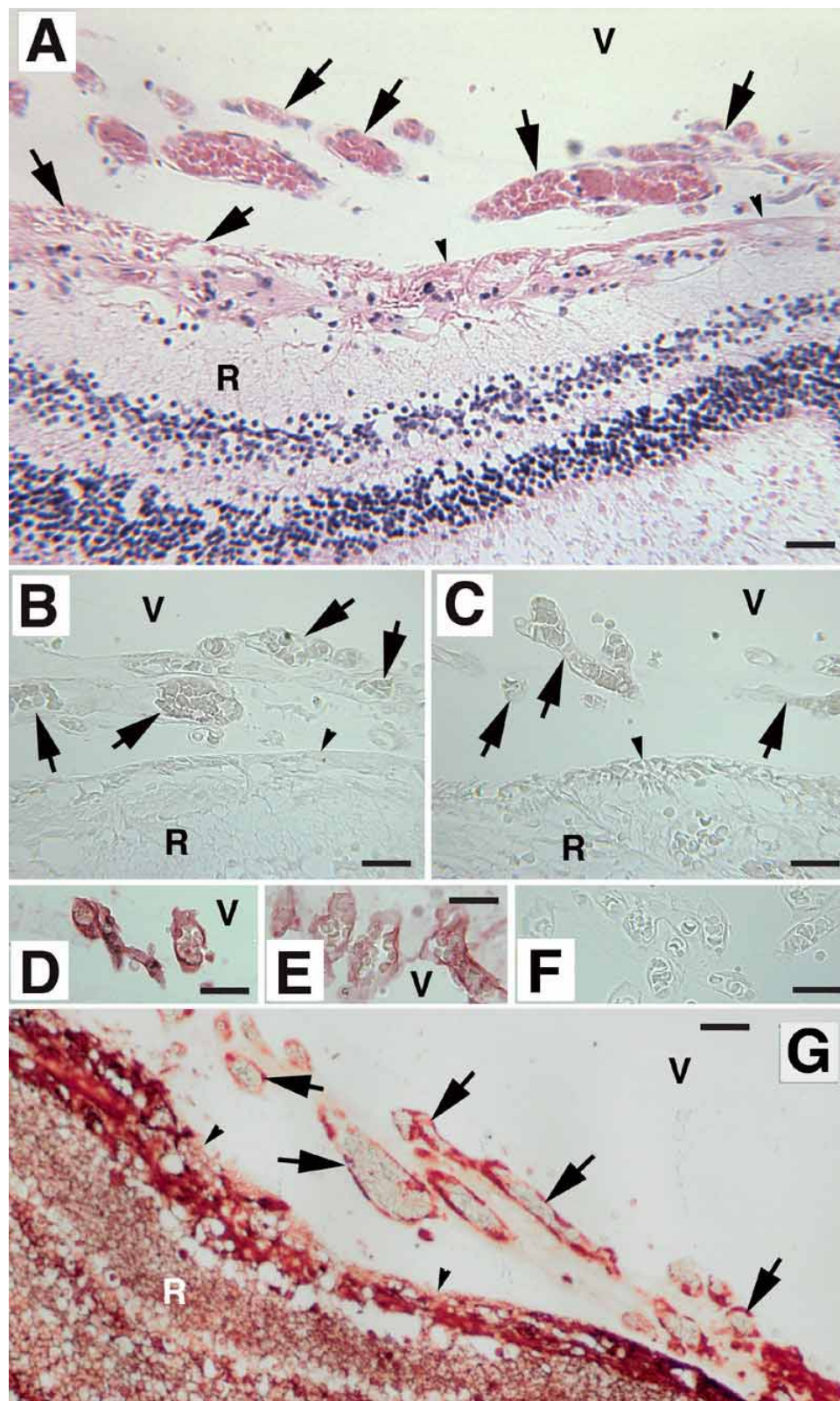


Figure 5. Analysis of Tbdn-1 protein expression in fetal human eye and in a case of human retinopathy of prematurity. **A-C,F,G:** Retinopathy of prematurity. **D,E:** Normal fetal human eye. Panels **B-F** were stained for Tbdn-1 expression. The small proliferative vitreal-retinal vessels (arrows in H&E stained low power section shown in **A**) growing from the retina into the vitreous humor in the ROP sample show little to no Tbdn-1 expression (**B,C**). **F:** ROP sections incubated with preimmune IgY showed no staining. Tbdn-1 expressed by blood vessels within Cloquet's Canal (**D**) and tunica vasculosa lentis (**E**) in a 19-week normal fetal human eye specimen without ROP. Blood vessels stain intensely red with antibody to Tbdn-1. **G:** Expression of α -tubulin in the ROP specimen showing high levels of the ubiquitous α -tubulin protein staining (red) both in the endothelial cells of the diseased neovascular areas of the vitreal-retinal regions and in the nonpathological areas of the ROP retina. **A-C,G:** The vitreous body is oriented at the top of the panel. The vitreous (V) and retina (R) are identified. Scale bars represent 25 μ m. The retinal inner limiting membrane is indicated by small arrowheads. Original magnification was 250x. No counterstain was used in micrographs **B-G** in order to be able to detect any low levels of Tbdn staining reactions (**B-F**) and in order to display the high level of ubiquitous tubulin staining in the ROP specimens (**G**). Micrographs shown are representative experiments.

mice (Figure 2), indicating that *Tbdn-1* levels were relatively restored at P26.

To further characterize the hyperoxia-induced retinal lesions, expression patterns of ASMA, a myofibroblast cell marker, and PCNA, a proliferating cell marker, were also analyzed by immunohistochemistry. A significantly higher level of expression of ASMA was detected in larger caliber abnormal blood vessels of the proliferative fibrovascular lesions of retinas of oxygen-reared mice when compared with little or no ASMA staining in retinal blood vessels of the examined eye sections of control mice reared in normoxia conditions (Figure 3, Figure 4). Nuclear expression of PCNA was significantly increased in endothelial cells in cross-sections of blood vessels of the retinal lesions of oxygen-induced animals compared to control animals which showed low levels of PCNA expression (Figure 3, Figure 4).

TBDN-1 expression is suppressed during retinopathy of prematurity in human: TBDN-1 immunolocalization was performed on a human fetus eye specimen (19 weeks age gestation) and a stage 3 ROP specimen to determine if TBDN-1 is expressed in pathological retinal blood vessels during the neovascularization phase of stage 3 ROP. H&E staining of sections of the ROP specimen revealed extensive inner retinal and vitreoretinal neovascularization consistent with stage 3 disease (Figure 5A). Eye sections from the ROP patient showed a lower level of expression of endothelial TBDN-1 protein in the diseased neovascular areas of the vitreal-retinal regions (Figure 5B,C) as compared to TBDN-1 levels expressed by blood vessels within Cloquet's Canal (Figure 5D) and tunica vasculosa lentis (Figure 5E) in an eye specimen from a 19 week human fetus without ROP, or compared to normal adult retinal vessels (not shown) and normal mouse neonate retinal vessels (Figure 1, Figure 2). Although there was faint TBDN-1 staining present in ROP blood vessels (Figure 5B,C), the level of staining was clearly lower than that observed in the specimen without ROP (Figure 5D,E) and slightly above the background levels observed in ROP sections incubated with a negative control IgY reagent (Figure 5F). As a positive immunohistochemistry control, eye section from the ROP patient showed a high level of expression of endothelial α -tubulin protein both in the diseased neovascular areas of the vitreal-retinal regions (Figure 5G) and in the nonpathological areas of the retina. These results suggest that *Tbdn-1* may not be expressed highly in abnormal proliferating vitreoretinal blood vessels in ROP.

DISCUSSION

Our results show that *Tbdn-1* expression is downregulated in the oxygen-induced experimental mouse model of retinopathy. The phenotype observed in neonatal wild type C57BL/6 mice reared in hyperoxia conditions was consistent with the response described in previous literature [15] and was characterized by the formation of retinal lesions displaying pronounced retinal thickening, extensive retinal neovascularization, and fibrovascular retinal growth. We previously observed that endothelial *Tbdn-1* expression increases before the vascular regression that mediates the remodeling

of the hyaloid vasculature in the developing mouse vitreous [16]. Our *Tbdn-1* knockdown model has demonstrated that *Tbdn-1* serves to block retinal neovascularization [14]. Knockdown of *Tbdn-1* in blood vessels in adult mice leads to the development of fibrovascular lesions accompanied by significantly increased neovascularization and thickening of the retina and choroid similar to human proliferative retinopathies [14]. Therefore, in the present study, we hypothesized that downregulation of *Tbdn-1* would precede maximal neovascularization in the oxygen-induced model of retinopathy. In the mouse oxygen-induced retinopathy model, maximal pathology peaks between P17-P21 and thereafter regresses [15]. Indeed we found that general suppression of *Tbdn-1* in the retinal blood vessels (outside the lesions) occurs prior to (P14-P16) and during (P17-P21) maximal retinal neovascularization in the oxygen-induced retinopathy model. In addition, a marked suppression of *Tbdn-1* (up to 81%) in the blood vessels of the retinal lesions is consistently observed at all time points examined (P14-P26). These results suggest that *Tbdn-1* loss may be involved in predisposing neonatal mice to retinal neovascularization.

The retinal pathology in hyperoxia-induced mice is also accompanied by a progressive increase in retinal tissue thickness. Although different in many ways to human ROP, the pathology seen in the oxygen-induced model is somewhat reminiscent of the retinal thickening seen in proliferative retinopathies in humans [18,19]. In addition, the hyperoxia-induced retinal lesions were similar in morphological appearance to those lesions we have observed in *Tbdn-1* knockdown mice [14] in which retinal neovascularization of different layers of the retina is accompanied by significant retinal thickening. Of importance is the finding that the decrease in *Tbdn-1* expression in proliferative retinal blood vessels of retinal lesions of hyperoxia-reared mice was accompanied by an increase in retinal blood vessel expression of the myofibroblast marker ASMA, and an increase in retinal endothelial expression of the proliferating cell marker PCNA. Myofibroblasts expressing ASMA are thought to be involved in the formation of retinal lesions possessing contractile forces that promote retinal detachment [20,21]. This pattern of suppressed retinal endothelial *Tbdn-1* combined with upregulated blood vessel ASMA in retinal lesions of hyperoxia-reared mice was akin to the pattern observed in the *Tbdn-1* knockdown retina [14]. Furthermore, the upregulated retinal endothelial PCNA is similar to that seen previously in vitreoretinal neovascularization of TGF- β 2 null fetal retinas, which is also accompanied by a suppression of *Tbdn-1* expression in the hyaloid vessels [16]. These results indicate that *Tbdn-1* loss and extensive remodeling of vitreoretinal blood vessels occurs in hyperoxia-induced retinopathy in mice. Although the mouse model of oxygen-induced retinopathy differs in several ways from human ROP, these results support a possible role of suppression of *Tbdn-1* expression in the pathogenesis of ROP.

Human stage 3 ROP and appropriate age-matched controls are very difficult to obtain. In this study we were fortunate to have access to a specimen of appropriately fixed and histologically processed ROP and to observe a lower level of

expression of TBDN-1 in this stage 3 ROP specimen compared to one 19 week human fetal eye specimen. The ROP specimen showed a low level of expression of endothelial TBDN-1 protein in the diseased neovascular areas of the vitreal-retinal regions. Many of these abnormal blood vessels had grown into the vitreous. We compared this staining level to the level of TBDN-1 expressed by blood vessels within Cloquet's Canal and the tunica vasculosa lenticis, which are both regions suspended in the vitreous body, in the fetal eye specimen from a subject without ROP. The absence of TBDN-1 expression in blood vessels of the ROP specimen was not due to the loss of blood vessel endothelial cells or to a loss of immunoreactivity of the tissue sections, because the ROP sections stained highly with an antibody to the ubiquitous pan tissue α -tubulin. Moreover, we have studied Tbdn-1 expression postnatally in mice and have found high levels of Tbdn-1 expression in retinal blood vessels of developing mice at stages analogous to the human ROP specimens analyzed (Figure 1). Furthermore, retinal endothelial TBDN-1 expression remains high in normal human adults [13]. Interestingly, sections of the eye from the ROP patient also showed a lower level of expression of endothelial TBDN-1 protein in nondiseased deeper retinal areas and the diseased neovascular areas. This suggests that a potential pan retinal effect in human ROP may include the suppression of TBDN-1 expression in regions other than those involved in immediate neovascular pathology. We have reported that a pan retinal effect occurs in the Tbdn-1 knockdown retina in which the suppression of retinal blood vessel basement membrane heparan sulfate proteoglycan is found throughout the Tbdn-1 suppressed retina as opposed to only in the neovascularized retinal lesions [14]. Previous studies by Berkowitz et al. [22] have also demonstrated that a pan retinal response to a carbogen challenge does indeed occur in the rat model of oxygen-induced retinal neovascularization. Collectively these studies suggest that a pan retinal effect could be a hallmark of oxygen-induced retinopathy and possibly also of ROP. Our results, although based only upon a single specimen, suggest that TBDN-1 may not be expressed in abnormal proliferating vitreoretinal blood vessels in ROP.

Given the possible link between tissue oxygen regulation and development of vitreoretinal neovascularization in ROP, a mechanistic explanation of the possible role of loss of Tbdn-1 expression in ROP emerges. Members of the Tbdn-1 family of molecules likely function in a holoenzyme complex and might regulate blood vessel proliferation by affecting the stability and the activity of proteins involved in regulating angiogenesis through acetylation. The acetyltransferase ARD1, which binds the mammalian Tbdn-1 homolog NAT-1, has been suggested to play a role in the targeted degradation and thus removal of HIF-1 α in mammals [7]. It is now well established that HIF-1 α regulates VEGF expression during hypoxia and can promote blood vessel proliferation through its induction of VEGF [6]. Suppression or absence of one or more of the acetyltransferase holoenzyme complex binding partners which regulate HIF-1 α stability might disrupt if not alter activity of

the complex. The disruption of acetyltransferase complexes involving ARD1 or Tbdn-1 might promote the stabilization of HIF-1 α and increase the production of growth factors promoting neovascularization in the retina. A study of the expression and function of Tbdn-1 family proteins in conjunction with the HIF-1 α pathway in both the oxygen-induced retinal neovascularization model and in human ROP would be informative to address these hypotheses.

The suppression of Tbdn-1 expression in retinal endothelium in retinal lesions of the hyperoxia-induced retinopathy model provides further evidence for an important role of Tbdn-1 expression for the maintenance of retinal blood vessel homeostasis through suppression of abnormal retinal blood vessel growth. Our transgenic *Tbdn-1* knockdown mouse model, which displays neovascular proliferative retinopathy, provides in vivo confirmatory evidence for the requirement of Tbdn-1 expression for the maintenance of normal retinal vascular homeostasis [14]. This, together with our preliminary but compelling evidence of TBDN-1 suppression in the retinal endothelium in a patient with ROP, supports our hypothesis of a contributing role for loss of TBDN-1 expression in the progression of neovascularization in proliferative retinopathies. TBDN-1 may serve as a valuable pathway for developing new therapies aimed at controlling ROP and other proliferative retinopathies.

ACKNOWLEDGEMENTS

We thank Lisa C. Adams and Dana S. Wall for technical assistance with histology and immunohistochemistry. We are grateful for support from Canadian Institutes of Health Research Operating Grants, Foundation Fighting Blindness-Canada Operating Grant, Canada Foundation for Innovation (HP, RLG), Atlantic Canada Opportunity Agency (Memorial University of Newfoundland), and NIH (U10EY012472 to WVG).

REFERENCES

1. Steinkuller PG, Du L, Gilbert C, Foster A, Collins ML, Coats DK. Childhood blindness. *J AAPOS* 1999; 3:26-32.
2. Good WV, Early Treatment for Retinopathy of Prematurity Cooperative Group. Final results of the Early Treatment for Retinopathy of Prematurity (ETROP) randomized trial. *Trans Am Ophthalmol Soc* 2004; 102:233-48.
3. Smith LE. Pathogenesis of retinopathy of prematurity. *Growth Horm IGF Res* 2004; 14:S140-4.
4. Smith LE. Pathogenesis of retinopathy of prematurity. *Semin Neonatol* 2003; 8:469-73.
5. Wheatley CM, Dickinson JL, Mackey DA, Craig JE, Sale MM. Retinopathy of prematurity: recent advances in our understanding. *Br J Ophthalmol* 2002; 86:696-700.
6. Ozaki H, Yu AY, Della N, Ozaki K, Luna JD, Yamada H, Hackett SF, Okamoto N, Zack DJ, Semenza GL, Campochiaro PA. Hypoxia inducible factor-1 α is increased in ischemic retina: temporal and spatial correlation with VEGF expression. *Invest Ophthalmol Vis Sci* 1999; 40:182-9.
7. Jeong JW, Bae MK, Ahn MY, Kim SH, Sohn TK, Bae MH, Yoo MA, Song EJ, Lee KJ, Kim KW. Regulation and destabilization of HIF-1 α by ARD1-mediated acetylation. *Cell* 2002; 111:709-20.

8. Hellstrom A, Perruzzi C, Ju M, Engstrom E, Hard AL, Liu JL, Albertsson-Wikland K, Carlsson B, Niklasson A, Sjedell L, LeRoith D, Senger DR, Smith LE. Low IGF-I suppresses VEGF-survival signaling in retinal endothelial cells: direct correlation with clinical retinopathy of prematurity. *Proc Natl Acad Sci U S A* 2001; 98:5804-8.
9. Benjamin LE, Hemo I, Keshet E. A plasticity window for blood vessel remodelling is defined by pericyte coverage of the pre-formed endothelial network and is regulated by PDGF-B and VEGF. *Development* 1998; 125:1591-8.
10. Hanahan D. Signaling vascular morphogenesis and maintenance. *Science* 1997; 277:48-50.
11. Hackett SF, Ozaki H, Strauss RW, Wahlin K, Suri C, Maisonpierre P, Yancopoulos G, Campochiaro PA. Angiopoietin 2 expression in the retina: upregulation during physiologic and pathologic neovascularization. *J Cell Physiol* 2000; 184:275-84.
12. Gendron RL, Adams LC, Paradis H. Tubedown-1, a novel acetyltransferase associated with blood vessel development. *Dev Dyn* 2000; 218:300-15.
13. Gendron RL, Good WV, Adams LC, Paradis H. Suppressed expression of tubedown-1 in retinal neovascularization of proliferative diabetic retinopathy. *Invest Ophthalmol Vis Sci* 2001; 42:3000-7.
14. Wall DS, Gendron RL, Good WV, Miskiewicz E, Woodland M, Leblanc K, Paradis H. Conditional knockdown of tubedown-1 in endothelial cells leads to neovascular retinopathy. *Invest Ophthalmol Vis Sci* 2004; 45:3704-12.
15. Smith LE, Wesolowski E, McLellan A, Kostyk SK, D'Amato R, Sullivan R, D'Amore PA. Oxygen-induced retinopathy in the mouse. *Invest Ophthalmol Vis Sci* 1994; 35:101-11.
16. Paradis H, Liu CY, Saika S, Azhar M, Doetschman T, Good WV, Nayak R, Laver N, Kao CW, Kao WW, Gendron RL. Tubedown-1 in remodeling of the developing vitreal vasculature in vivo and regulation of capillary outgrowth in vitro. *Dev Biol* 2002; 249:140-55.
17. Lehr HA, Mankoff DA, Corwin D, Santeusano G, Gown AM. Application of photoshop-based image analysis to quantification of hormone receptor expression in breast cancer. *J Histochem Cytochem* 1997; 45:1559-65.
18. Speicher MA, Danis RP, Criswell M, Pratt L. Pharmacologic therapy for diabetic retinopathy. *Expert Opin Emerg Drugs* 2003; 8:239-50.
19. Panozzo G, Gusson E, Parolini B, Mercanti A. Role of OCT in the diagnosis and follow up of diabetic macular edema. *Semin Ophthalmol* 2003; 18:74-81.
20. Bochaton-Piallat ML, Kapetanios AD, Donati G, Redard M, Gabbiani G, Pournaras CJ. TGF-beta1, TGF-beta receptor II and ED-A fibronectin expression in myofibroblast of vitreoretinopathy. *Invest Ophthalmol Vis Sci* 2000; 41:2336-42.
21. Gandorfer A, Rohleder M, Kampik A. Epiretinal pathology of vitreomacular traction syndrome. *Br J Ophthalmol* 2002; 86:902-9.
22. Berkowitz BA, Penn JS. Abnormal panretinal response pattern to carbogen inhalation in experimental retinopathy of prematurity. *Invest Ophthalmol Vis Sci* 1998; 39:840-5.